

FORENSIC NEUROPATHOLOGY
WILLIAM A. COX, M.D.
FORENSIC PATHOLOGIST/NEUROPATHOLOGIST

CRANIAL NERVE II/Visual Pathway

June 17, 2011

General Information

Before we discuss injuries to **cranial nerve II (optic nerve)** we need to review the anatomy of the visual pathway. Once you have an understanding of the anatomy, you can then appreciate why some of the injuries produce the changes in vision they do.

EARLY MORPHOGENESIS OF THE EYE

In the embryological development of the eye, it is the multiplication of cells, as well as the directional change in shape, structure, and function of the cells which governs growth. Gene determination decides on the direction in which changes occur, whereas the reciprocal demands of the individual cells or groups of cells determine how far that direction must be followed. Fundamentally, the process consists of two activities: change in structure and shape due to relatively different rates of growth and change in structure and function due to differentiation and functional specialization.

There is ample evidence that abnormalities that occur during the first few weeks after fertilization may be responsible for many ocular malformations that occur in humans.

Gastrulation (formation of the mesodermal germ layer) occurs early in gestation, typically day 20 in humans. The primitive streak forms as a longitudinal groove within the epiblast, which represent the future ectoderm of the bilaminar embryonic disc.

Epiblast cells migrate medially toward the primitive streak where they invaginate to form the mesodermal layer (Fig. 1). This forms the classic three germ layers: ectoderm, mesoderm, and endoderm. Gastrulation progresses in a cranial (head) to caudal (foot) direction.

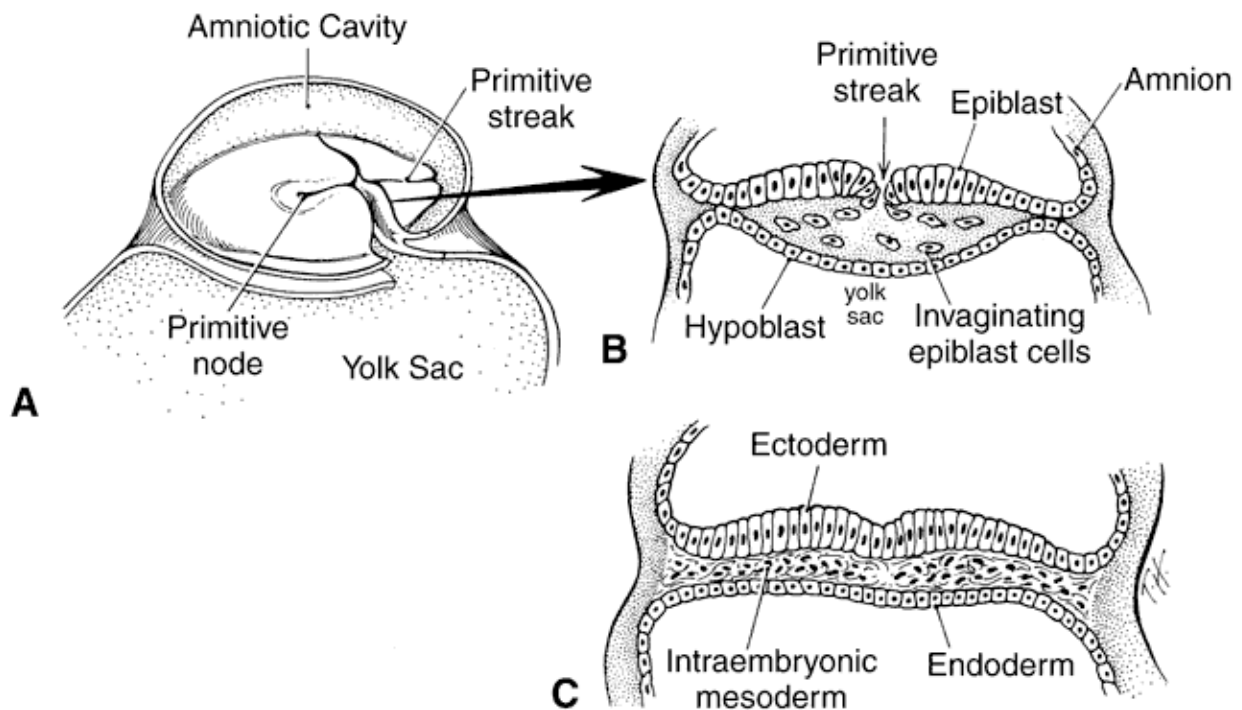


Fig. 1. A. This is a drawing of a 17-day-old embryo in gastrulation stage, dorsal view, with the amnion removed. B. This represents a cross-section of a 17-day-old embryo through the primitive streak. The primitive streak represents invagination of epiblast cells between the epiblast and hypoblast layers. Note that the epiblast cells filling the middle area form the mesodermal layer. C. This is a cross-section of the embryo at the end of the third week showing the three definitive germ layers: ectoderm, mesoderm, and endoderm. Cook CS, Sulik KK, Wright KW: Embryology. In Wright KW [ed]: Pediatric Ophthalmology and Strabismus, pp 3-43. St. Louis: Mosby, 1995.

Concurrently, cranial surface ectoderm proliferates forming bilateral elevations called neural folds (Fig. 2). Columnar surface ectoderm in this area now becomes neural ectoderm.

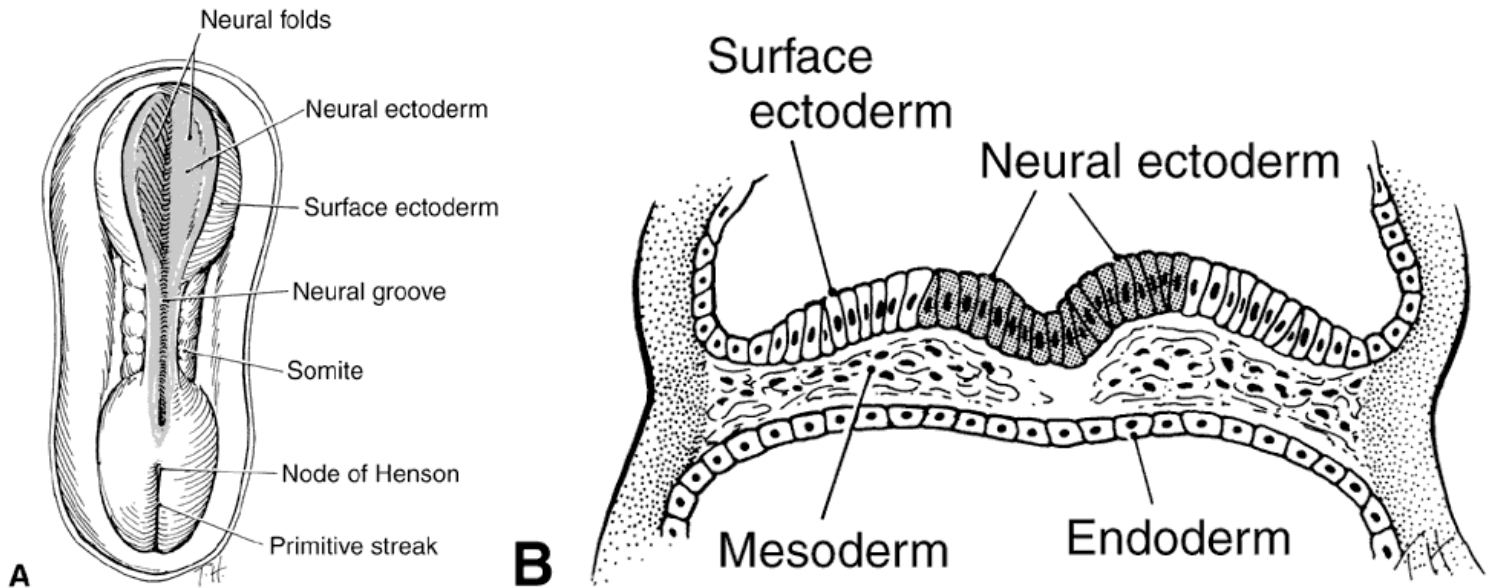


Fig. 2. A. This is a drawing of the dorsal view of a human embryo at 19 to 20 days' gestation. The neural plate transforms into two neural folds on each side of the neural groove. The neural groove in the middle of the embryo is shaded to represent neural ectoderm; the unshaded surface of the embryo is the surface ectoderm. B. This is a cross-section of the same embryo through the neural plate. Ectoderm in the area of the neural groove (shaded cells) has differentiated into neural ectoderm, whereas the ectoderm on each side of the neural groove is surface ectoderm (clear white cells). (Cook CS, Sulik KK, Wright KW: Embryology. In Wright KW [ed]: Pediatric Ophthalmology and Strabismus pp 3-43. St. Louis: Mosby, 1995.)

One of the things that we have learned is that exposure to teratogens, even for a brief period of time, during gastrulation can have disastrous effects in later ocular development. Exposure to ethanol or retinoic acid during a short period equivalent to the third week of human gestation causes primary damage to the forebrain neural ectoderm. This results in a myriad of malformations such as microphthalmia, anterior segment dysgenesis (Peters' anomaly), iris and optic nerve colobomas (a hole in one of the structures of the eye, such as the iris, retina, choroid or optic disc), and persistent hyperplastic primary vitreous.

As the neural folds elevate and approach each other (neurulation), a specialized population of mesenchymal cells, the neural crest, emigrates from the neural ectoderm at its junction with the surface ectoderm. In the development of the eye, the neural ectoderm (deriving from the neural plate and neural folds), the surface ectoderm, the neural crest, and, to a lesser extent, the mesoderm are all of importance.

The embryonic origins of ocular tissues is as follows:

Neural Ectoderm (optic cup)

Neural retina, retinal pigment epithelium, pupillary sphincter and dilator muscles, posterior iris epithelium, ciliary body epithelium and the optic nerve.

Neural Crest (connective tissue)

Corneal endothelium, trabecular meshwork, stroma of the cornea, iris, and ciliary body, ciliary muscle, choroid and sclera, perivascular connective tissue and smooth muscle cells, meninges of optic nerve, orbital cartilage and bone, connective tissue of the extrinsic ocular muscles, secondary vitreous and zonules.

Surface Ectoderm (epithelium)

Corneal and conjunctival epithelium, lens, lacrimal gland, eyelid epidermis, eyelid cilia, epithelium of adnexa glands, and epithelium of the nasolacrimal duct.

Mesoderm (muscle and vascular endothelium)

Extraocular muscle cells, vascular endothelia, Schlemm's canal endothelium and blood.

The cranial nerve crest contributes most of the connective tissues of the eye and its adnexal structures. The hyaluronic acid-rich extracellular matrix influences migration and differentiation of the neural crest cells. The acellular matrix is secreted by the surface epithelium as well as the neural crest cells and forms a space through which crest cells migrate. Fibronectin secreted by the noncrest cells forms the limits of the mesenchymal migration. Interactions between the migrating neural crest and the associated mesoderm appear to be essential for normal crest differentiation. Many congenital malformations of the anterior segment and cornea probably arise from derangements in the axial migration of ocular neural crest.

The optic primordium is a thickened zone in the differentiating central nervous system that forms the neural folds of the early embryo. Some of the neuroepithelium composing the optic primordium becomes the future optic cup and stalk; some cells may delaminate to contribute to the neural crest. The optic sulcus or groove arises in the primordium at the time when the neural folds are still open in the forebrain (Fig. 3 and 4A).

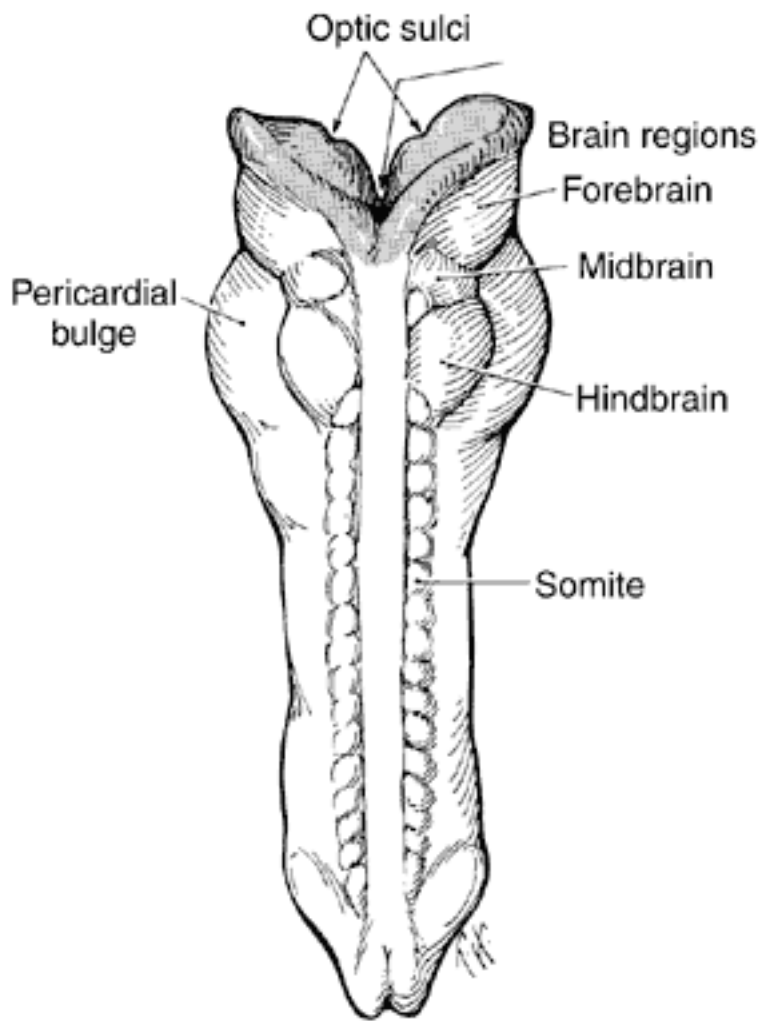


Fig. 3. This is a drawing of a 23-day-old embryo, dorsal view, showing partial fusion of the neural folds. Brain vesicles have divided into three regions: forebrain, midbrain, and hindbrain. Facing surfaces of the forebrain are lined with neural ectoderm (shaded cells), but most of the embryo is now lined with surface ectoderm (clear white) because the neural groove has closed. On the inside of both forebrain vesicles is the site of the optic sulci. (Cook CS, Sulik KK, Wright KW: Embryology. In Wright KW [ed]; Pediatric Ophthalmology and Strabismus, pp 3-43. St. Louis: Mosby, 1995.)

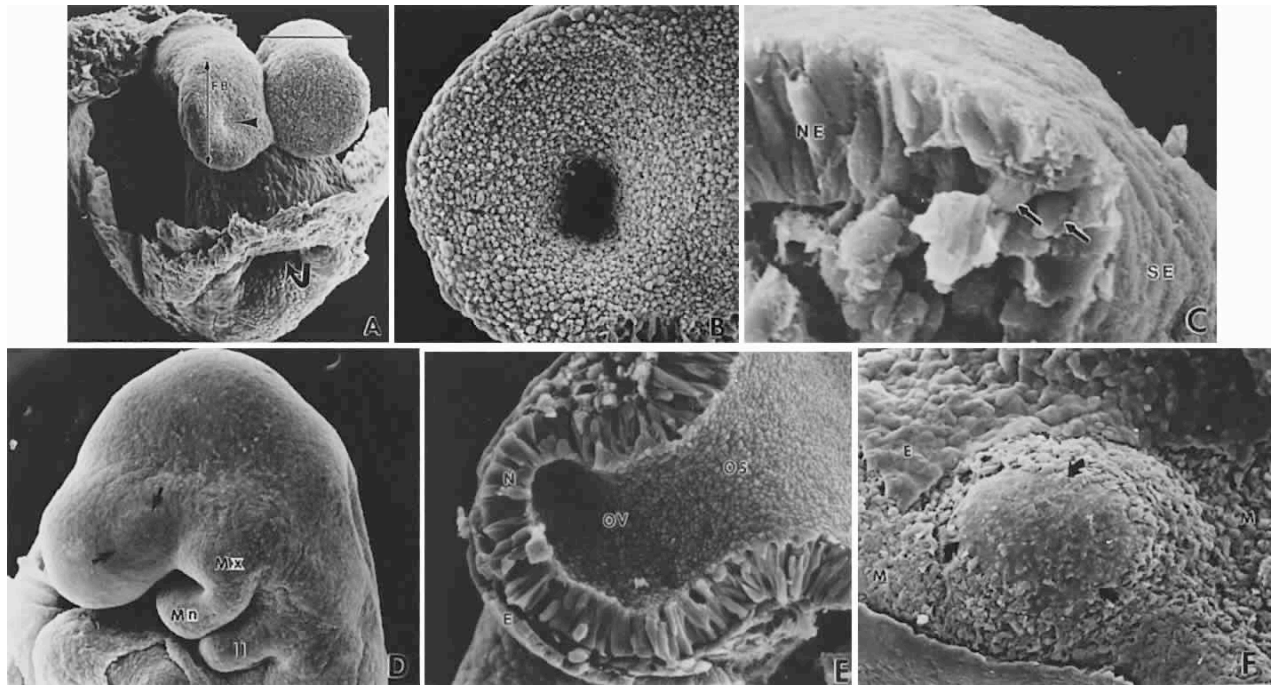


Fig 4. Formation of optic sulcus and vesicle. Mouse embryos are illustrated and follow a sequence nearly identical to that observed in human embryos. A. A scanning electron micrograph of a mouse embryo at day 8 (6 somite pairs) equivalent to the human at 4 weeks' gestation. Arrowhead indicates the optic sulcus, an evagination of the forebrain (FB). The entrance to the foregut is indicated by the curved arrow. B. Optic sulcus continues to deepen through a process of microtubule-mediated elongation and microfilament-mediated apical constriction. C. Embryo fractured through the midbrain in a plane indicated by the horizontal line in Fig. 2A. Note the junction between the columnar neural ectoderm (NE) and the flattened surface ectoderm (SE). This is the area from which the mesenchymal neural crest cells emigrate (arrows) to join the underlying mesoderm. These mesencephalic neural crest cells will populate the area around the optic primordia and give rise to most of the ocular connective tissue. D. Embryo of 25 somite pairs (fifth week in a human), the bulge of the enlarging optic vesicle (arrows) can be appreciated externally. Mx, maxillary prominence of the first visceral arch; Mn, mandibular prominence of the first visceral arch; II, second visceral arch. E. Frontal fracture at the level of the optic vesicle (OV). The optic vesicle is lined by the columnar neural ectoderm (N) and enlarges, approaching the surface ectoderm (D). The optic stalk (OS) is continuous with the cavity of the forebrain. F. Removal of the surface ectoderm (E) from an embryo of 25 somite pairs reveals the exposed basal lamina of the optic vesicle (arrows). Enlargement of the optic vesicle has displaced the adjacent mesenchyme (M) so that the basal lamina of the surface ectoderm (E) is in direct contact with that of the other optic vesicle.

With enlargement of the sulcus, the optic evaginations and, later, the optic pits appear in the region of the future forebrain (see Fig. 4B). The portion of the evaginations adjacent

to the midbrain contacts the mesencephalic neural crest cells, which will form the mesenchymal envelope, isolating neural from surface ectoderm (see Fig. 4C). At about the 24th day with the closure of the neural tube, the optic pits are pushed outward away from the central nervous system and toward the surface ectoderm. The lateral bulges, caused by the outward extension of the growing optic pits, become pouch-shaped vesicles at about the 25th day of development (20 somite pairs) (Fig. 5; Fig. 4D and E).

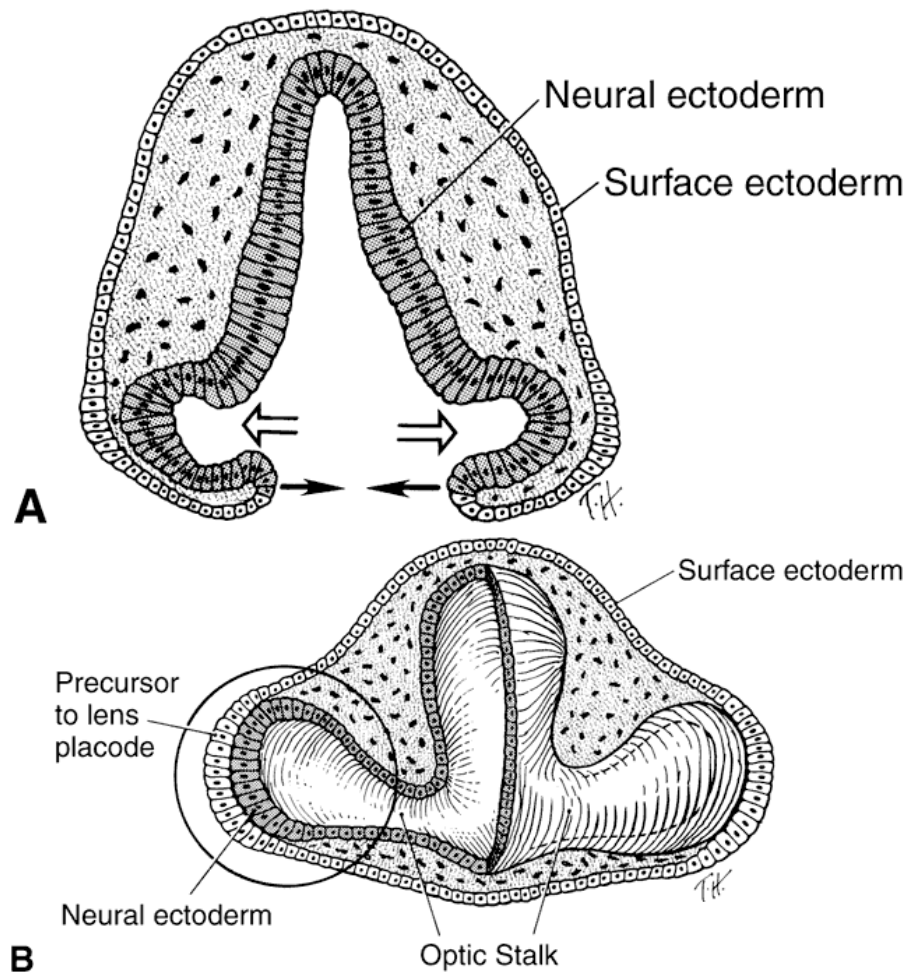


Fig 5. A. This is a drawing of a cross-section through the forebrain and optic sulci of a 24-day-old embryo. Note that the neural tube is still open. The optic sulci are lined by neural ectoderm (shaded cells), while the surface forebrain is covered with surface ectoderm (clear white cells). As the optic sulci (neural ectoderm) evaginate toward the surface ectoderm (hollow arrows), the edges of the brain vesicles move together to fuse, thus closing the neural tube (solid arrows). B. This is a drawing of a cross-section through a 26-day-old embryo at the level of the optic vesicle. Note that the neural tube is

closed, the surface ectoderm now lines the surface of the forebrain, and the neural ectoderm is completely internalized. The surface ectoderm cells overlying the optic vesicles enlarge to form the early lens placode. (Cook CS, Sulik KK, Wright KW: Embryology. In Wright KW [ed]; Pediatric Ophthalmology and Strabismus, pp 3-43. St. Louis; Mosby, 1995.)

Before I continue I need to define the term 'placode'. A placode is an area of thickening in the embryonic epithelial layer where some organ or structure later develops. The term usually refers to cranial placodes, peripheral nervous system structures associated with the special senses and cranial ganglia. The placodes associated with the special senses are: The otic placode, which forms the otic pit and the otic vesicle, giving rise eventually to organs of hearing and equilibrium; the lens placode, under the direction of the optic vesicle gives rise to the lens of the eye and the olfactory placode (or nasal placode), which gives rise to the olfactory epithelium of the nose. Placodes also develop in the formation of other structures, such as teeth and feathers.

The optic vesicles become sheathed with cells of neural crest origin that, except for a small region in the center of the bulge, separates them from the surface ectoderm (see Fig. 4E). The future primordium of the retina is present before closure of the neural tube, when the neural ectoderm is still open to the amniotic cavity. The optic stalk is formed by a constriction of the area between the vesicle's cavity and ciliated, and its outer surface, as well as the inner aspect of the surface ectoderm overlying it, is covered by a thin basal lamina.

The next event is the invagination of the optic vesicles by differential growth and buckling to form the optic cup (Figs. 6 to 9). The temporal and lower walls move inward against the upper and posterior walls. This process also involves the optic stalk so that

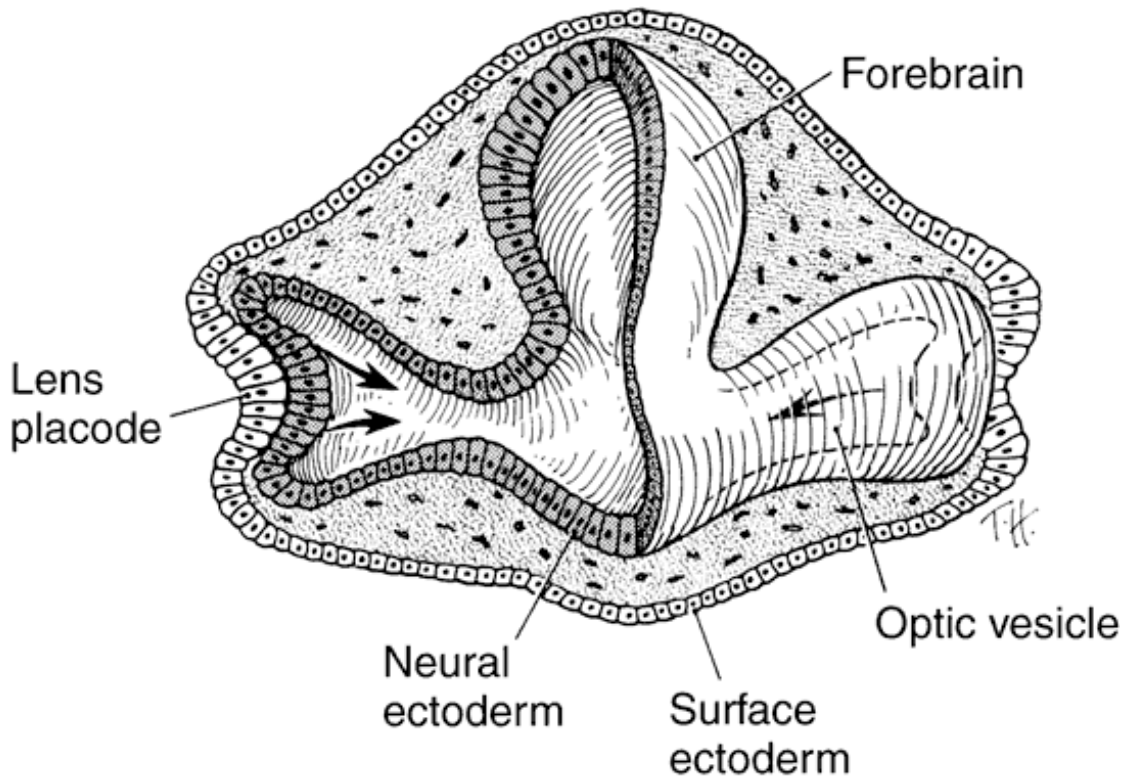


Fig. 6. This is a drawing of a transection through a 28-day-old embryo showing invaginating lens placode that is pushing into the optic vesicle (arrows), thus creating the optic cup. Note the orientation of the eyes 180 degrees from each other. This is also illustrated in Figures 9B and C. (Cook CS, Sulik, Wright KW; Embryology. In Wright KW [ed]; Pediatric Ophthalmology and strabismus, pp 3-43. St. Louis: Mosby, 1995.

the optic (choroid/embryonic/retinal) fissure is formed where the two laterally growing edges of the cup and stalk meet. Mesenchyme (primarily neural crest) penetrates immediately into the cup by filling up the fissure.

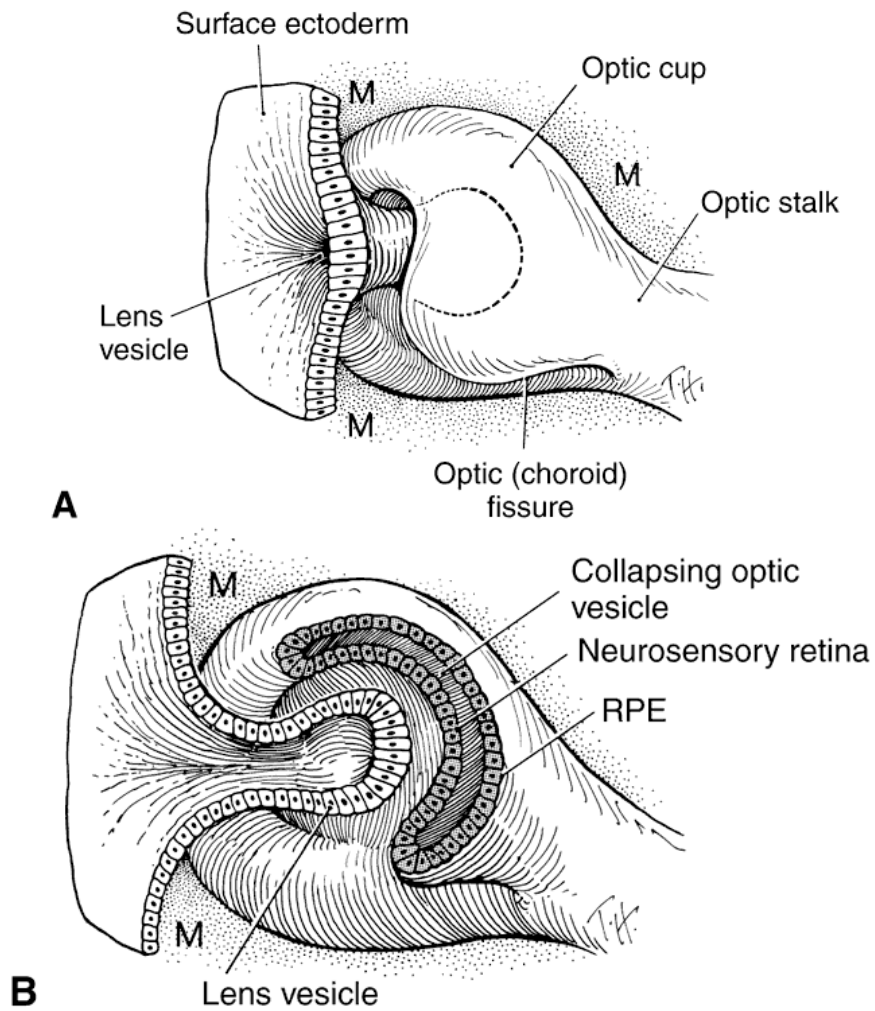


Fig. 7. This is a drawing that shows the formation of the lens vesicle and optic cup. Note the optic fissure is present because the optic cup is not fused inferiorly. Mesenchyme (M) surrounds the invaginating lens vesicle. Note that the optic cup and optic stalk are made of neural ectoderm. (Cook CS, Sulk KK, Wright KW: Embryology. In Wright KW [ed]: Pediatric Ophthalmology and Strabismus, pp 3-43. St. Louis: Mosby, 1995.

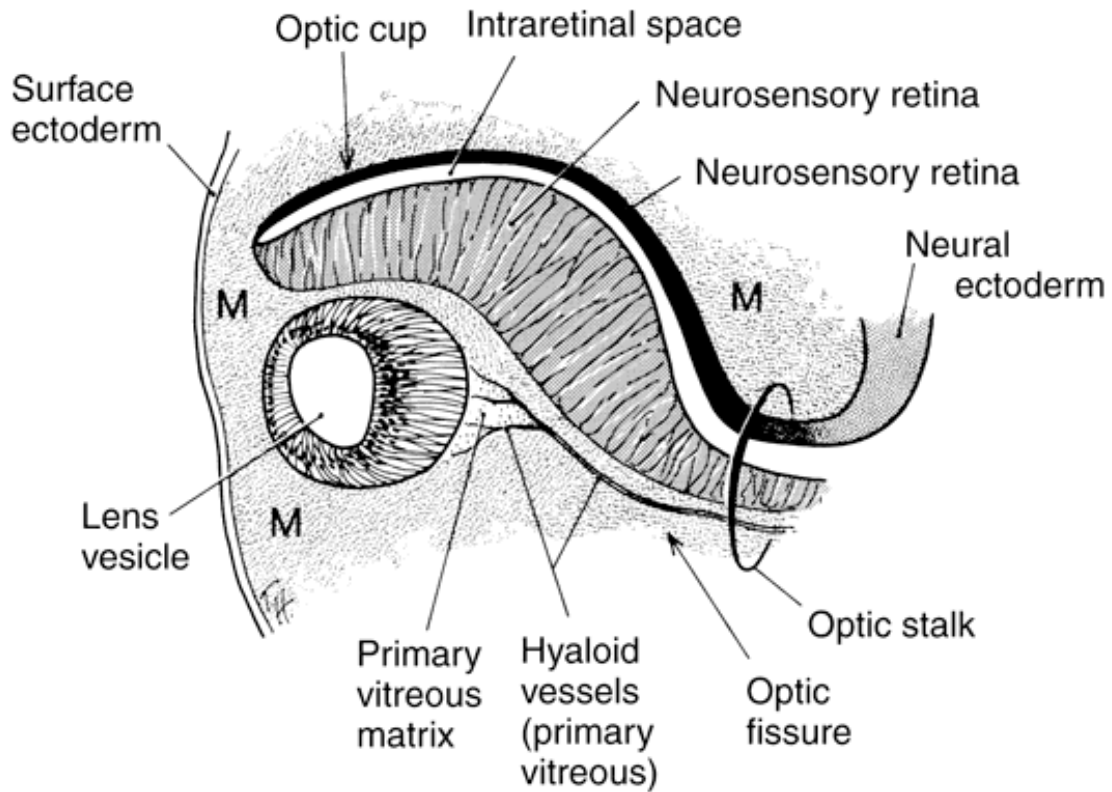


Fig. 8. This is a drawing of a cross-section at approximately 5 weeks' gestation through the optic cup and optic fissure. The lens vesicle is separated from the surface ectoderm. Mesenchyme (M) surrounds the developing lens vesicle and the hyaloid artery is seen with the optic fissure. See also Figure 9F. (Cook CS, Sulik KK, Wright KW: Embryology. In Wright KW [ed]: Pediatric Ophthalmology and Strabismus, pp 3-43. St. Louis: Mosby, 1995.)

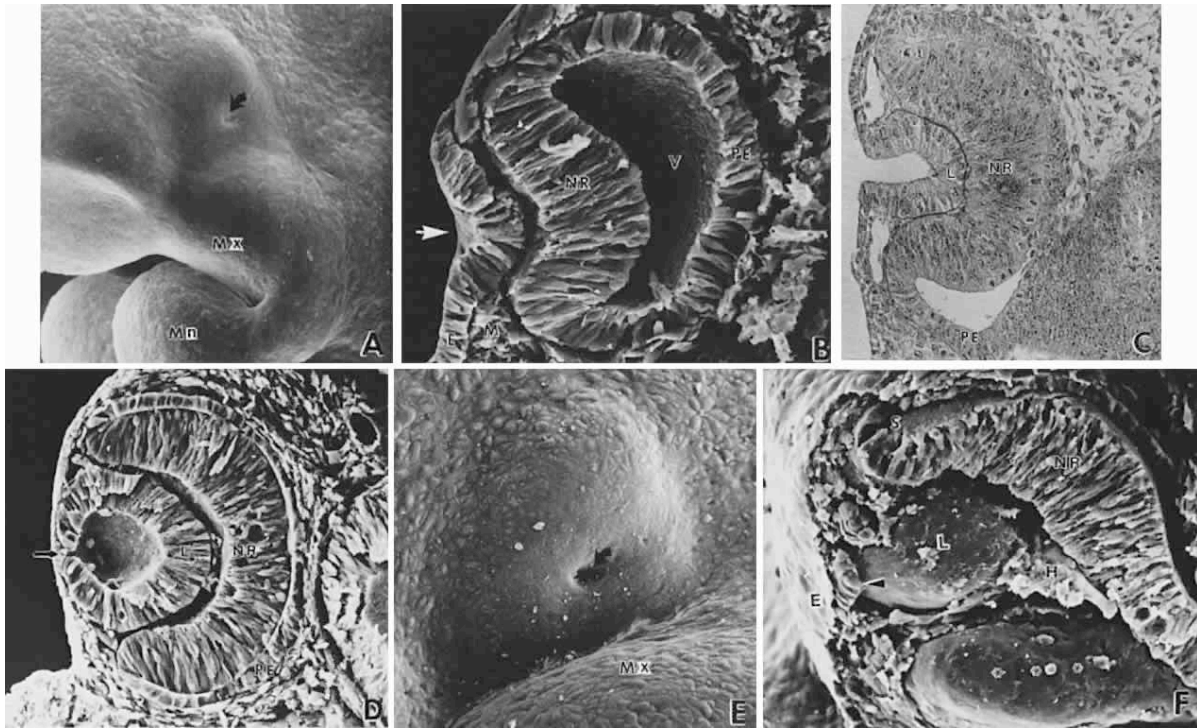


Fig. 9. Invagination of the optic cup and lens vesicle. Mouse embryos are illustrated. A. Embryo of somite pairs (fifth week in a human). On external examination, the invaginating lens placode can be seen (arrow). Note its position relative to the maxillary (Mx) and Mandibular (Mn) prominences of the first visceral arch. B. Embryo of the same age as in Figure 3A. Frontal fracture through the lens placode (arrow) illustrates the associated thickening of the surface ectoderm (E). Mesenchyme (M) of neural crest origin is adjacent to the lens placode. Distal portion of the optic vesicle thickens concurrently, as the precursor of the neural retina (NR), whereas the proximal optic vesicle becomes a shorter, cuboidal layer that is the anlage of the retinal pigmented epithelium (PE). The cavity of the optic vesicle (V) becomes progressively smaller. C. Epithelium of the lens placode continues to invaginate (L). There is an abrupt transition between the thicker epithelium of the placode and the adjacent surface ectoderm, which is not unlike the transition between the future neural retina (NR) and the future pigmented epithelium (PE). D. As the lens vesicle enlarges during the eleventh day, the external opening, or lens pore (arrow), becomes progressively smaller. The lens epithelial cells at the posterior pole of the lens elongate to form the primary lens fibers (L). NR, anlage of the neural retina; PE, the anlage of the pigmented epithelium (now a very short cuboidal layer). E. External view of the lens pore (arrow) and its relationship to the maxillary prominence (Mx). F. Frontal fracture reveals the optic fissure (*) where the two sides of the invaginating optic cup meet. This forms an opening in the cup allowing access to the hyaloid artery (H), which ramifies around the invaginating lens vesicle (L). The former cavity of the optic vesicle is obliterated except in the marginal sinus (S), at the transition between the neural retina (NR) and the pigmented epithelium, E, surface ectoderm.

The optic vesicle and optic stalk invaginate through differential growth and infolding. Local apical contraction and physiologic cell death have been identified during the

invagination. This process progresses from inferior to superior so that the sides of the optic cup and stalk meet inferiorly in the optic fissure. The two lips of the optic fissure meet and initially fuse anterior to the optic stalk with fusion progressing anteriorly and posteriorly. Failure of normal closure of this fissure may result in inferiorly located defects (colobomas) in the iris, choroid, or optic nerve.

Closure of the optic cup through fusion of the optic fissure allows establishment of intraocular pressure. Studies have demonstrated that, in the chick, the protein in the embryonic vitreous humor is derived from plasma proteins entering the eye by diffusion out of permeable vessels in the anterior segment. After optic fissure closure, protein content in the vitreous decreases, possibly through dilution by aqueous humor produced by developing ciliary epithelium.

RETINAL MORPHOGENESIS

Early Differentiation

The primordium of the retina is present at the optic pit stage early during the third week of gestation even before closure of the neural tube (see Fig. 4A and B). The anterior part of the optic vesicle, the retinal disc, is the future neural retina, and has a marginal non-nucleated layer in contact with the lens placode. The sides of the invaginating vesicle are destined to become the pigment epithelium (see Fig. 9C and D).

Following vesicle invagination to form the optic cup, the inner layer has an outer nuclear zone and an inner anuclear marginal zone. The outermost layer of cells of the nuclear zone (the germinating, or proliferative layer) projects cilia to the surface of the contacting outer layer, or future pigment epithelium. These cilia disappear during the seventh week. They are replaced by the precursors of the photoreceptor outer segments during the fourth month.

The outer layer of the cup has two to three layers of pseudostratified columnar cells that enclose pigment granules at 33 days' gestation. This layer produces the earliest pigmentation in the body. Punctate tight junctions near their apical ends join the cells. The basal lamina that originally surrounded the optic vesicle remains continuous over the inner (vitreous) and other surfaces of the optic cup.

The primitive retinal cells rest on a basement membrane that faces the inner future vitreal aspect and extend their apices toward the pigmented epithelial cells. In general, mitotic figures occur in the outer zone and prevail longest in the outer surface layer adjacent to the space representing the remnant of the primary optic cavity; and at the margin of the optic cup (future ciliary body-iris region). Mitosis first ceases in the central area; growth goes on longer in the periphery. Most cell division in the presumptive retina occurs before 15 weeks.

Formation of Retinal Layers

Retinal differentiation commences when mitosis has practically stopped. It spreads from areas facing the future vitreous (marginal zone) toward the primary optic cavity, and from the center of the base of the optic cup (inner neuroblastic layer) toward its edge. Retinal ganglion cells and Muller's cells generally develop almost simultaneously. Here also, however, a gradient exists, given the axons and dendrites of ganglion cells near the optic nervehead differentiate earlier than those situated at the periphery. By proliferation and migration of cells, the neural epithelium separates into inner and outer neuroblastic layers in the seventh week of gestation (Fig. 10E and F)

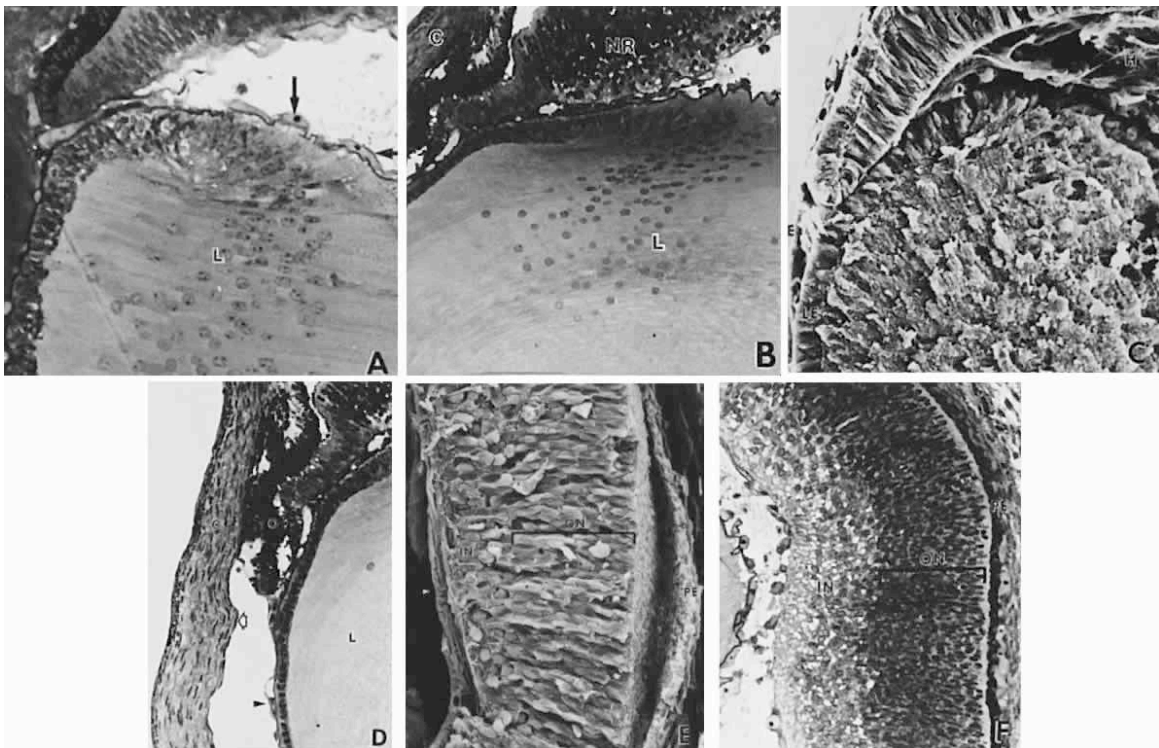


Fig. 10. Formation of the lens fibers; early retinal differentiation. A. Elongation of the lens fibers located nearest to the neural retina forms the embryonal lens nucleus (L) and obliterates the lens vesicle cavity. The endothelial cells that form the tunica vasculosa lentis are indicated by arrows. B. Formation of the secondary lens fibers is apparent as elongation of the epithelial cells at the equatorial lens bow. C. cornea; NR, neural retina; L, lens. C. Electron micrograph evaluation of the developing lens (L). LE, anterior lens epithelium, E, surface ectoderm. D. Corneal endothelium (open arrow) and stroma (C) are completely formed but the anterior iridial stroma and iridocorneal angle (*) structures are still immature and covered by the endothelium. The outer, pigmented layer of the optic cup (O), which forms the pupillary sphincter and dilator muscles, is in apposition to the cornea in the area of the future aqueous outflow pathways (*). The arrowhead indicates the capillaries of the anterior tunica vasculosa lentis. L, lens. E and F. The retina has segregated into an inner neuroblastic layer (IN) containing the primitive ganglion cells the axons of which form the nerve fiber layer (arrow), and an outer neuroblastic layer (ON) containing the primordia of the photoreceptors, retinal interneurons, and glial cells. PE, retinal pigment epithelium.

A few days later, a definite narrow nerve fiber layer is established, occasionally traversed by the radial fibers of the Muller cells.

Immature ganglion cell bodies move into the inner neuroblastic layer along with other less mature cells, presumably future amacrine cells, creating in their wake a nuclei-free entanglement of processes, the transient fiber layer of Chievitz (Figs. 11A and 12A). With further realignment of cells, this layer is mostly obliterated by 8 to 10 weeks gestation. At this period, the cells of the inner and outer neuroblastic layers intermingle by means of their cytoplasmic extensions. They fill up the previously acellular Chievitz layer; cell bodies shift positions, establishing a new, comparatively cell-free zone of intertwined processes, the inner plexiform layer (approximately 10.5 weeks) (see Figs. 11B and 12B). With the emergence of the inner plexiform layer, an inner nucleated layer, consisting mostly of the cell bodies of ganglion cells, becomes separated from an outer neuroblastic zone. The cell bodies of the Muller's cells and the developing amacrine cells are located near the inner border of the outer neuroblastic zone. Bipolar cells differentiate mostly from the middle portion of this outer zone, whereas horizontal cells and photoreceptors arise from its outermost region (see Fig. 11B and C, and Fig. 12B and C).

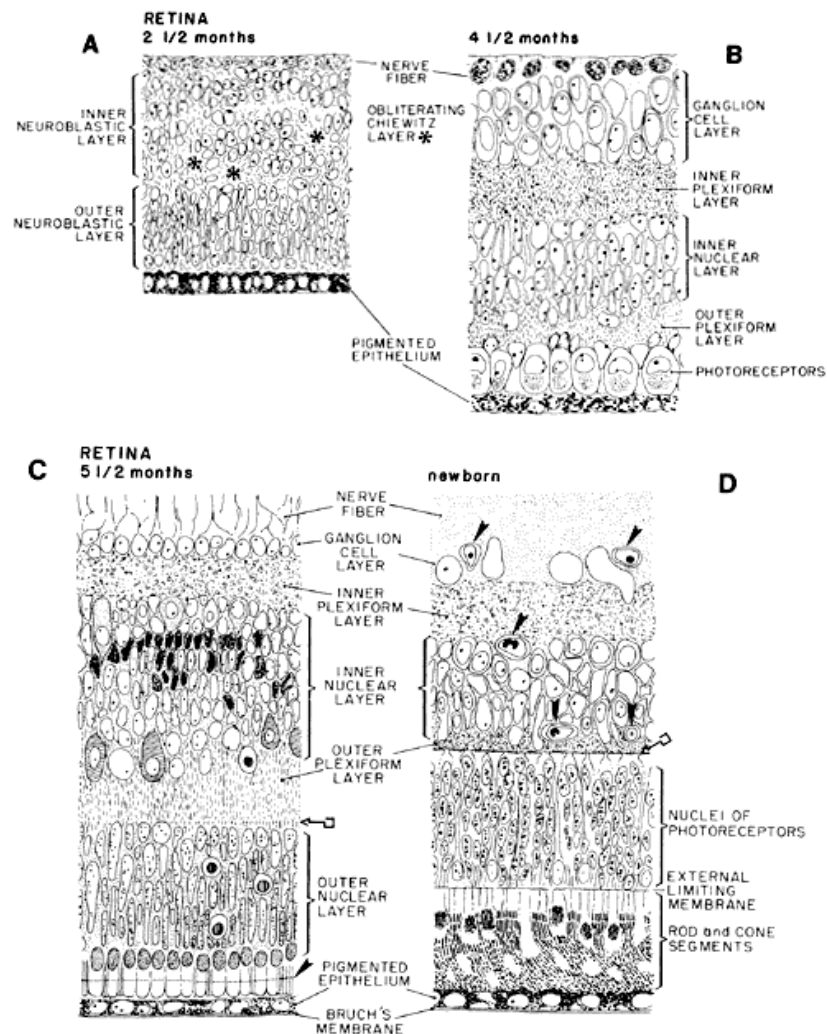


Fig. 11. Schematic diagram of the developing retina. Region of the posterior pole is represented in sagittal section in every diagram. A. At 2½ months, transient fiber layer of Chievitz, which separated the inner from the outer neuroblastic layers of the primitive retina, is slowly being obliterated by shifting of the nuclear elements and realigning of their processes. Uppermost cells, lying vitread, are differentiating into ganglion cells. Those below the uneven transient layer of Chievitz (*) are immature, but destined to differentiate into amacrine and Muller cells. The future inner plexiform layer will be located between the shifted nuclei of the latter and those of the ganglion cells. The outer neuroblastic layer contains photoreceptor, bipolar and horizontal cell elements. B. At midterm (4½ months), retinal lamination is essentially complete. The ganglion cells have a multilayered arrangement. The inner plexiform layer, composed of fibers of bipolar, ganglion and amacrine cells supported by mullerian fibers, has established sites of primitive conventional and ribbon synapses. In the inner nuclear layer, the still undifferentiated cellular components are recognizable by shape and position. In the outer nuclear layer, large cone nuclei are aligned adjacent to the pigment epithelium and the smaller rod nuclei are positioned more vitread. The outer plexiform layer has primitive

lamellar synapses between bipolar cell dendrites and cone pedicles, which are not shown. Photoreceptor outer segments are not yet present. C. At 5.5 months, the ganglion cells have thinned out to one to two layers (except in the macular layer). The cellular components of the inner nuclear layer include amacrine cells with large pale nuclei in the innermost (vitread) zone of this layer; and pleomorphic, dark-staining mullerian cell nuclei; both these types originally came from the inner neuroblastic layer. Also included are the smaller bipolar cells and large, pale-staining horizontal cells that are in an irregular arrangement sclerad. These two cell types are derived from the outer neuroblastic layer, together with the photoreceptors. The outer plexiform layer has a linear arrangement of synapses between bipolar cells and rod spherules (key symbol). The outer nuclear layer consists of six to seven layers of nuclei; the outermost are cones aligned to the external limiting membrane. Growing photoreceptor outer segments projected into the space between pigment epithelium and external limiting membrane (arrowhead). Cell death is represented by the round dark-centered symbols. D. Newborn retina has the adult configuration with vascularization (arrowheads) reaching the outer limits of the inner nuclear layer. Outer plexiform layer is thinner than that in the adult, but the line of synapses is well established (key symbol). Rod and cone inner and outer segments are fully developed and the tips of the outer segments contact the pigment epithelium.

These developmental processes are well under way by 10 weeks to 12 weeks, when an identifiable outer plexiform layer separates the immature horizontal and bipolar cell nuclei from those of the photoreceptors.

Synaptogenesis precedes development of photoreceptor inner and outer segments by almost 2 months. Lamellar synapses start to form early in the fourth month in the cone axons and bipolar terminals, as well as conventional synaptic complexes associated with amacrine cells; when these phenomena are operable, the cells are still immature.

The newborn's retina has configuration and layers of the adult's. The photoreceptor outer segments are well developed and in contact with the pigment epithelium. Synapses of the outer plexiform layer are apparent (see Figs. 11D and 12D).

Early in retinal morphogenesis, limiting membranes are established. Junctions of the zonula adherens type, representing the external limiting membrane of the retina are present in the fifth week between the outer plasma membranes of adjacent neuroblasts. A thin basal lamina exists over the inner surface of the marginal layer even before the lens vesicle formation. Contribution of basal lamina-like material from developing

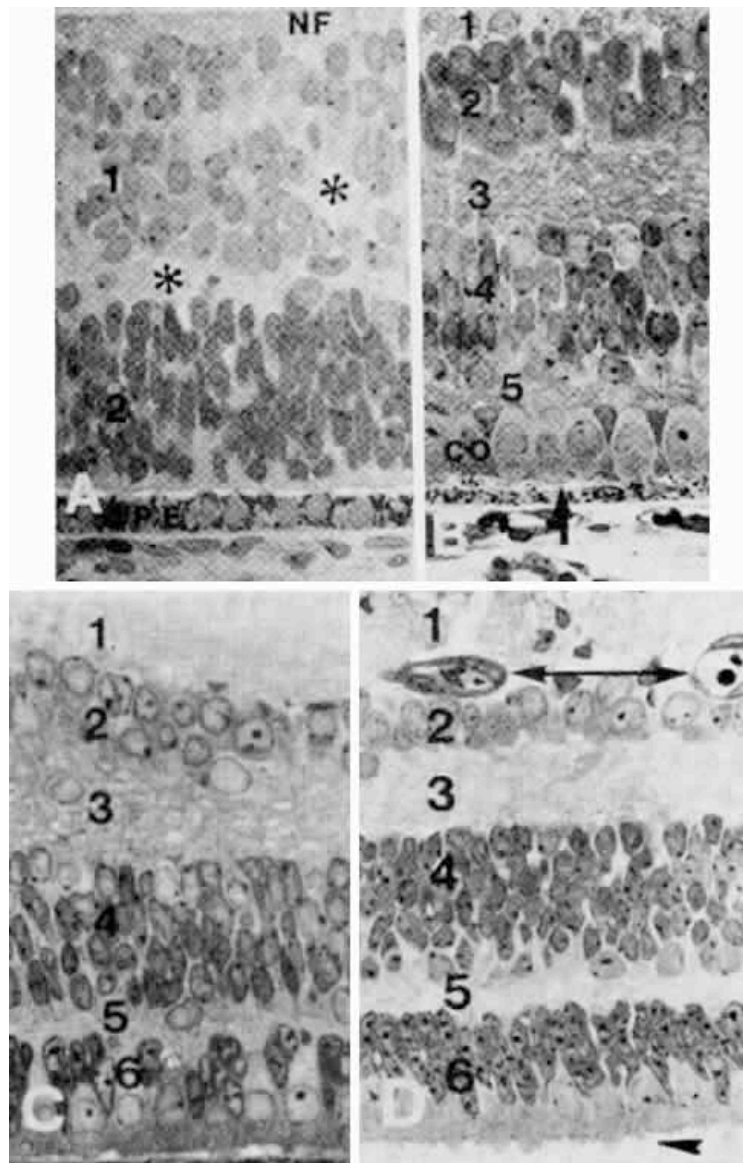


Fig. 12. A. Portion of retina at the fundus of a fetus at about 10 weeks gestation. The inner neuroblastic layer (1) is separated from the outer neuroblastic layer (2) by a slowly disappearing layer of Chievitz (*). The pigment epithelium (PE) has a single layer of cells. NF, nerve fiber layer. B. Portion of the central area from a monkey retina at 76 days, comparable with that of a human at 3.5 to 4 months. 1, nerve fiber layer; 2, ganglion cell layer; 3, inner plexiform layer; 4, inner nuclear layer; 5, narrow outer plexiform layer. Cone nuclei (co) are aligned next to the external limiting membrane (arrow). C. Section through a portion of the retinal fundus of a macaque fetus at 86 days (comparable with that of a human at midterm). 1, nerve fiber layer; 2, ganglion cell layer; 3, inner plexiform layer; 4, inner nuclear layer; 5, narrow outer plexiform layer; 6, outer nuclear layer. D. Section through the fundus of a retina at approximately 5.5 months. The numbering of the layers is as in C. Double-headed arrow indicates blood vessels in the ganglion cell layer. Arrowhead on the bottom points to photoreceptor inner

segments protruding into the extracellular space beyond the external limiting membrane. (B and C from Smelser GK, Ozanics V, Rayborn M, Sagun D: Retinal synaptogenesis in the primate. Invest Ophthalmol 13:340-361, 1974.)

Muller's cell processes combines with it to form the primitive internal limiting membrane.

OPTIC NERVE AND DISC

Optic Stalk

The optic stalk forms a connecting channel between the vesicular cavities and that of the forebrain around the 24th day of gestation. (see Fig. 4E). Its involution commences simultaneously with the collapse of the vesicles into the optic cup stage at about day 29. A shallow groove is formed in the stalk (see Fig. 9F), extending from the optic (choroid) fissure almost to the forebrain. During this same period of time (24 to 29 days of gestation), the hyaloid artery is within this depression. Some drainage from the sinusoids surrounding the optic cup occurs through a tributary of the primitive maxillary vein. This channel, also located within the optic stalk groove, is probably the precursor of the future central retinal vein. Direct continuity exists between the inner layers of the cup and stalk (Fig. 13A); the region of the disc is outlined by the neuroepithelial tissue of the primitive papilla.

Closure of the optic fissure commences during the fourth week with fusion of the central part of the optic cup. Its inner and outer margins fuse subsequently; closure of the cup is complete at 5 weeks (Fig. 14; see Fig. 13A). The lips of the optic stalk begin to close over the hyaloid artery starting from the region near the forebrain and gradually extending distally (see Fig. 13A and B). Thus, fusion of the margins of the stalk lags behind that of the optic cup.

The margins of the optic fissure are covered by basal lamina. Breakdown of the basal lamina, inversion of the outer layers of the cup and stalk, degeneration of the superfluous cells, and eventual reconstitution of the basal lamina are essential events in normal closure.

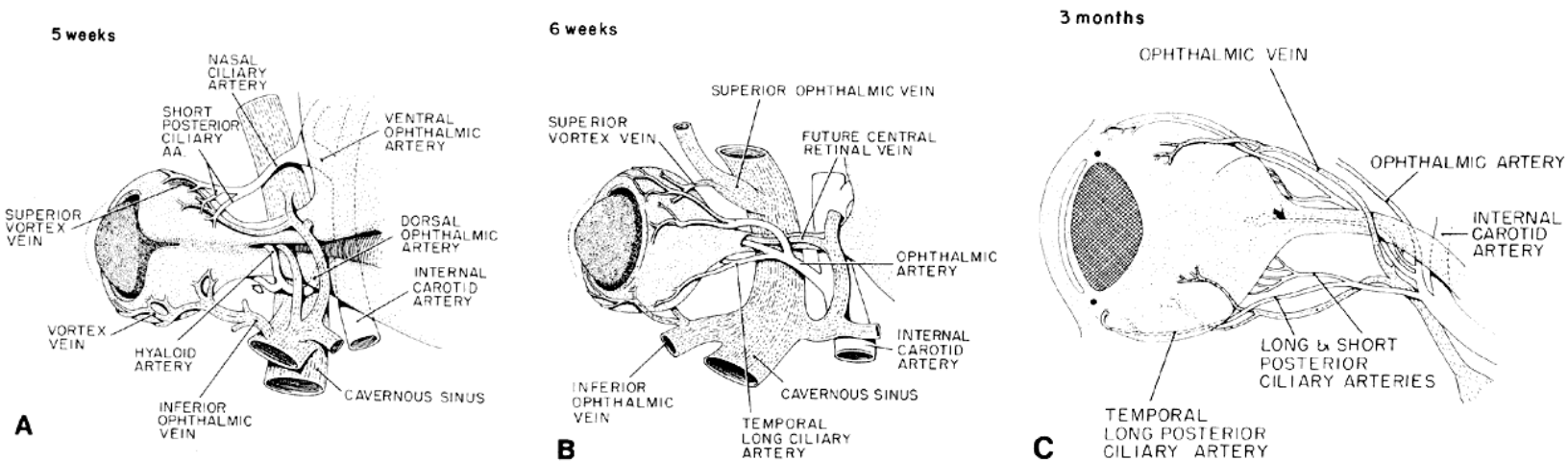


Fig. 13. This is a schematic drawing of the optic stalk and early optic nerve formation; their relation to the periocular vasculature. A. Developing optic vesicle and stalk seen from below. Embryonic fissure of the cup is closed except for a notch at the tip. It remains open in the stalk. The hyaloid artery and a terminal branch of the dorsal ophthalmic artery from the internal carotid artery are trapped within the fissure, as is a small twig from the maxillary vein. The other branch of the dorsal ophthalmic artery, which continues outside the cup, is the temporal long ciliary artery (hallow arrow). The ventral ophthalmic artery has a transitory anastomosing branch with the dorsal ophthalmic. The nasal ciliary artery came off this connection, which then disappeared (not shown), so that the dorsal ophthalmic artery eventually remains the only branch from the internal carotid to the eye (see B). Upper and lower venous plexuses draining the blood channels in the mesenchyme next to the pigment epithelium form the primitive superior and inferior vortex veins that connect with the cavernous sinus. B. By 6 weeks, the proximal portion of the fetal fissure is closed up to the small opening for the hyaloid vessels. The interior of the eye is drained by terminal branches of the maxillary vein, which accompany the hyaloid artery and eventually empty into the cavernous sinus. (Redrawn from the film *Embryology of the Eye*). C. Relation of the growing optic nerve of the vessels supplying the intraocular structures. The optic nerve has grown to 7 to 8 mm in length and 1.2 mm in width and its orbital portion is being vascularized from the septa. Hyaloid artery is marked by curved arrow.

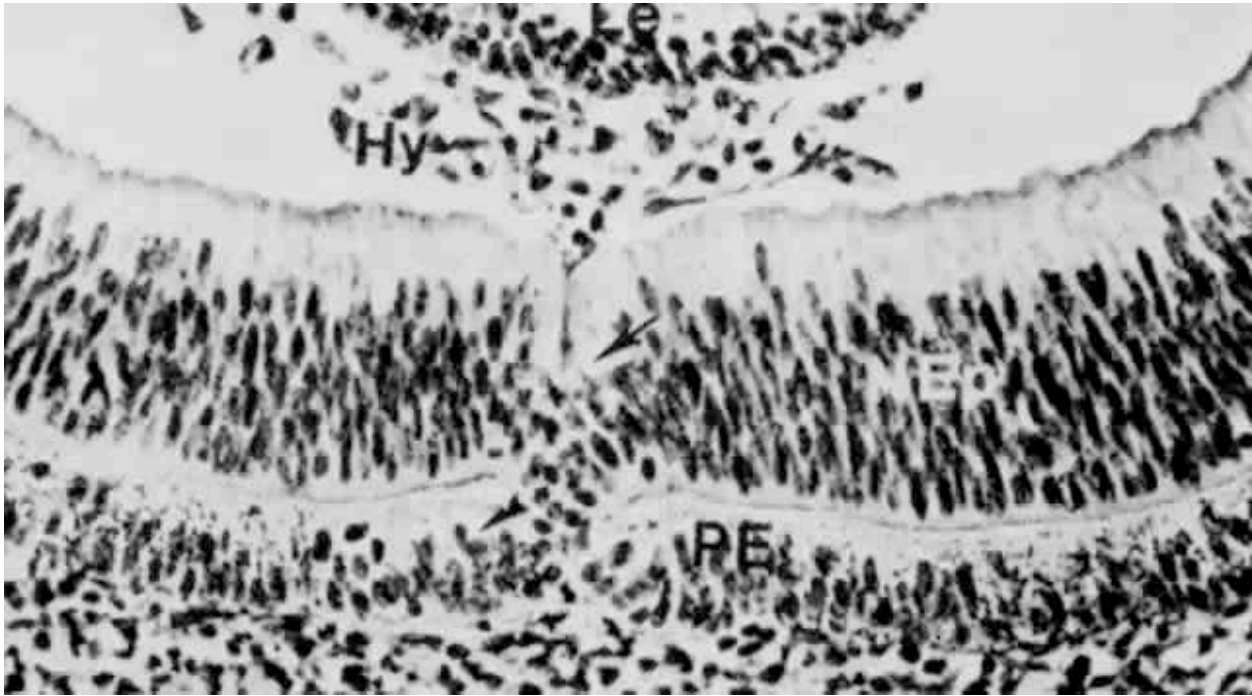


Fig. 14. Almost completely fused embryonic (or optic) fissure has discarded cells around the contacting margins of the optic cup (arrow). Arrowhead indicates pigment epithelium (PE) without pigment granules around the region of fusion. Hy, arborization of hyaloid artery; NEP, neural epithelium.

Migration of Nerve Fibers into the Inner Stalk Layer

Some cells in the inner wall of the optic stalk vacuolate and receive axons from the ganglion cells of the retina. The fibers force their way through these spaces, the fused optic stalk is almost completely filled by nerve fibers that surround the hyaloid artery. The primitive epithelial papilla with the hyaloid artery in its center is isolated by the confluent axons that course toward the brain. There is a potential space between the basal lamina around the hyaloid, which is covered by glia, and the basal lamina of the retinal surface, where the hyaloid artery enters from the papilla. This space between the artery and the glial sheath are converted to glia, which become the constituents of the primitive optic disc. Some of these glia are destined to form a conical formation around the hyaloid artery, called Bergmeister's papilla (Fig. 35). The cells of this last structure proliferate; by 4.5 months, there is a mantle around the regressing artery. The extent of

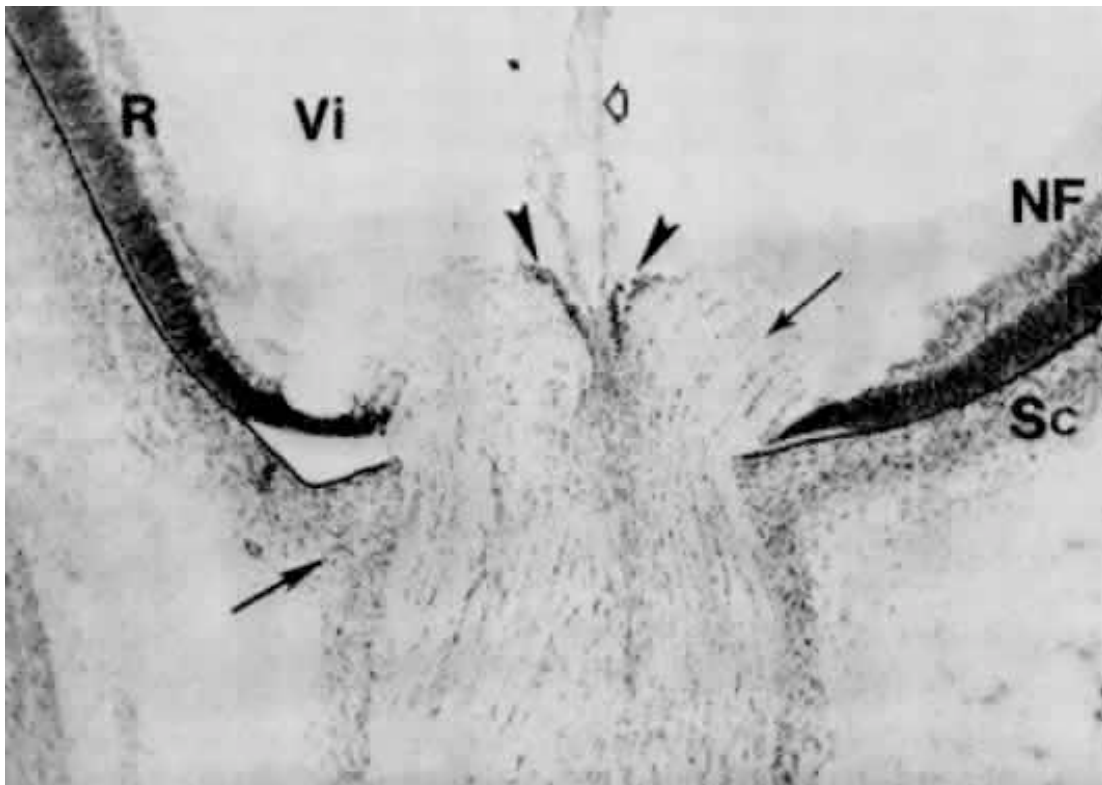


Fig. 15. This is a section through the optic nerve-head of a fetus at 3 months. Bergmeister's papilla (arrowheads) represent the neuroepithelial cells that were displaced toward the center of the optic stalk around the hyaloid artery's entrance at the time when the axons of the ganglion cells made their right angle turn to pass through the stalk. Glial cells of the papilla also extend around the hyaloid artery as its sheath (hollow arrow). Optic nerve fiber bundles surrounded by rudimentary glial septa make a nearly right angle turn toward the scleral foramen (double arrows). Scleral condensation (Sc) merges into that of the developing dura mater (arrow). The inner nuclear and ganglion cell layers end sooner than the outermost cells of the outer nuclear layer of the retina at the exit of the optic nerve fibers. NF, nerve fiber layer; R, retina, Vi, secondary vitreous.

the degeneration of these cells late in gestation defines the limit of the excavation at the disc.

Lamina Cribrosa

The collagenous fibers of the sclera progress from the perilimbal region posteriorly, where they encircle the developing optic nerve, thus forming the scleral foramen. In the fourth month, connective tissue fibers penetrate the optic nerve, running between groups of glia-covered axons to reach the hyaloid vessel. Thereafter, a network of collagenous and elastic fibers forming a sieve-like scaffolding, the lamina cribrosa, bridges the scleral foramen. The latter attains its mature structure during the seventh month. It should be

emphasized that the openings filled with axons are present first, and the “sieve” subsequently invades around them. A faint suggestion of the optic nerve sheath commences in the seventh week, but it is precisely defined only in the fifth month (see Fig. 15). The sheaths are derived from the cranial neural crest mesenchyme. By the end of the third month, the optic nerve is 1.2 mm in diameter and 7 to 8 mm long (see Fig. 13 C).

Myelination

Myelination starts in the fetus near the chiasm about the seventh month, progresses distally and stops at the lamina cribrosa about 1 month postpartum. In the newborn, the myelin is extremely thin and seems to contain more cholesterol in the portion near the brain. During childhood, the number of myelin layers around the axons increases.

Retina

As indicated above, the retina arises as an evaginated portion of the brain called the optic pouch. This pouch invaginates to form a two-layered optic cup. The outer layer forms

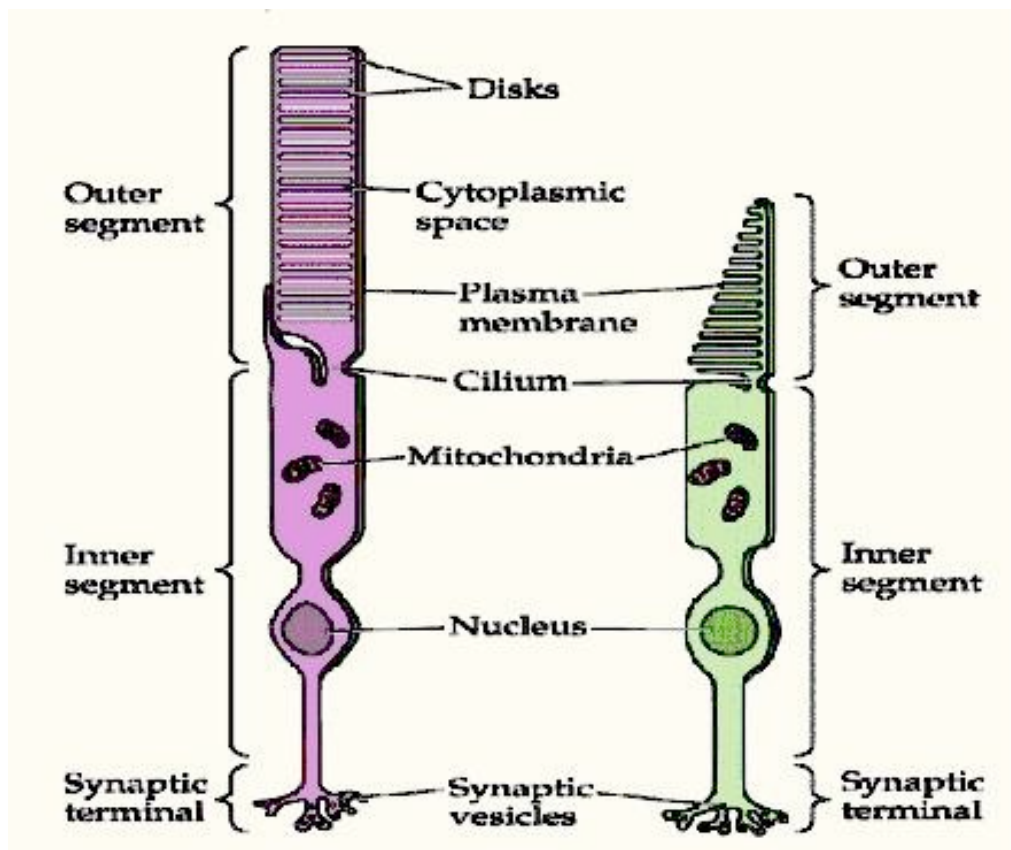


Fig. 16. In the above illustration the left figure is a rod, which is reacts to low intensities of illumination and the right a cone, which is a color receptor and for sharp visual definition.

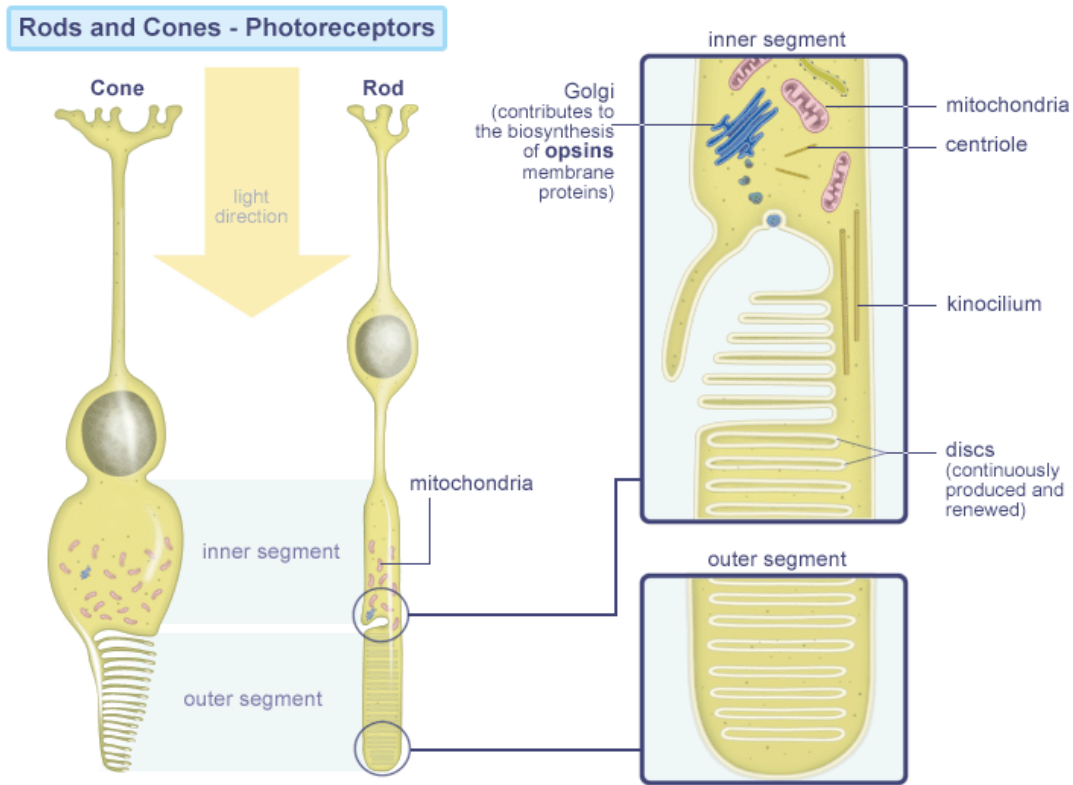


Fig. 17. This illustration gives a more detailed picture of the rods and cones

the pigmented epithelium. The inner layer forms the neural portion of the retina, which in turn gives rise to the bipolar rod and cone cells, the bipolar and horizontal neurons, which stay within the retina, and the multipolar ganglionic neurons whose axons form the optic nerves.

The rod and cone cells react to light. The cones, of which there are 3 types, are stimulated by light of relative high intensity. They are responsible for sharp visual definition and for color discrimination in adequate illumination. There are approximately 4.5 million cones in the human eye, which tend to decrease in number towards the periphery of the retina. The rods, whose number is estimated at 100 to 120

million, react to low intensities of illumination and are responsible for twilight and night vision.

Close to the posterior pole of the eye, the retina contains a small circular area called the macula lutea, which is in direct line to the visual axis. The macula represents the retinal area for central vision. The eyes are always fixed in such a way that the retinal image of any object is always focused on the macula. The rest of the retina is concerned with paracentral and peripheral vision. Within the macula, the inner layers of the retina are pushed apart, forming a central depression called the fovea centralis. The fovea centralis constitutes the point of sharpest vision and most acute color discrimination.

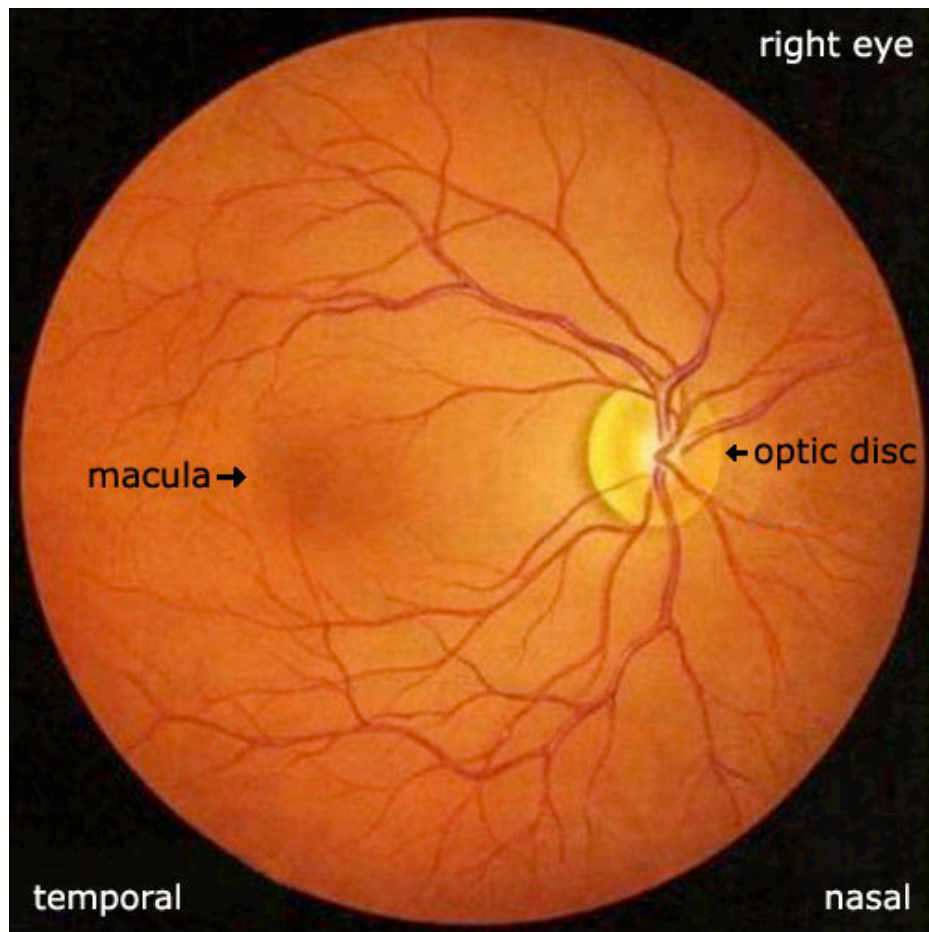


Fig. 18. This is a photo of what the macula looks like through an ophthalmoscope.

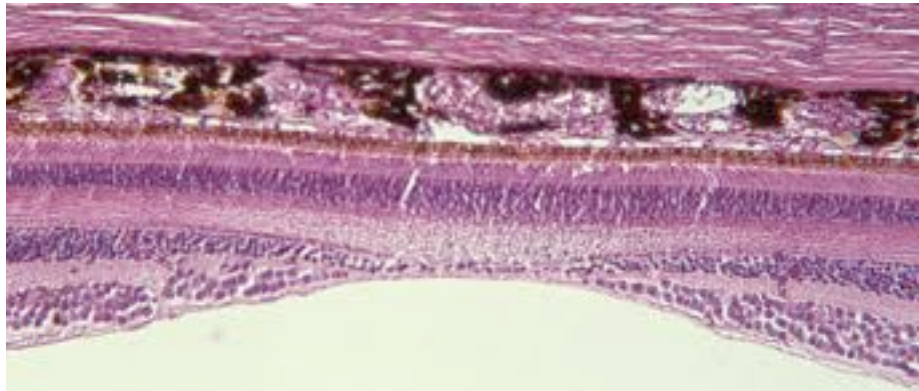
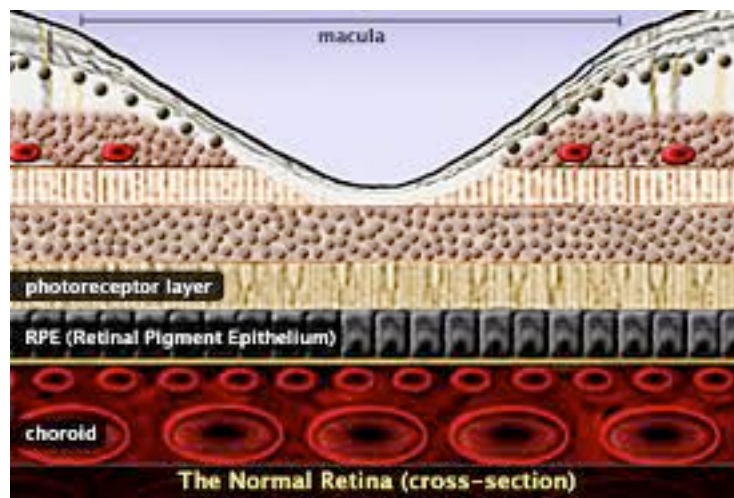


Fig. 19 (upper image). This is a drawing of the macula. Fig. 20 (lower image). This is an actual photomicrograph of the macula of the retina.

Here the retina is composed entirely of closely packed slender cones. Cones are responsible for our color and day vision. People who lose functioning of their cones are legally blind and obviously cannot perceive color. A point to remember is that the photoreceptors (rods and cones) in humans, like human auditory hair cells, are permanent cells that do not divide and are not replaced if destroyed by disease.

The rods and cones are composed of an outer segment, a narrow neck, an inner segment, a cell body and a synaptic base. Functionally the rods and cones consist of three areas: the outer segment, located on the outer surface of the retina and is responsible for phototransduction; the inner segment, being separated from the outer segment by the neck, contains the nucleus and most of the biosynthetic machinery; and the synaptic

terminal, which makes contact with the photoreceptor's target cells. Photopigments are present in the outer segments; where the photochemical reactions to light take place that in turn give rise to signals, which are ultimately transmitted to the visual cortex. The outer segment is composed of a series of laminated discs derived from the infolding of the plasma membrane (see above illustrations). The photo pigments are bound to the membranes of the discs and are constantly renewed. In rods, the folds are pinched off from the plasma membrane resulting in the disc being free-floating, whereas in the cones the discs remain part of the plasma membrane (Fig. 16 and 17).

Rhodopsin is the photopigment of rods in primates, which is extremely sensitive to light, having the ability to respond to a signal photon of light; hence rods function well in the dim light that is present at dusk or at night, when most stimuli are too weak to excite the cones. This is due to the fact that rods contain more photosensitive visual pigment than cones, enabling them to capture more light; more importantly, rods amplify light signals more than cones do. Consequently a signal photon of light can evoke a detectable electrical response in a rod; in contradistinction to this, a single cone requires tens or hundreds of photons to evoke similar response. In addition, rods use convergence to strengthen the signals evoked by a signal photon of light through many rods synapsing on the same target interneuron, which is a bipolar cell. This leads to the signals from the rods being pooled in the bipolar cells and thus reinforcing one another, thus increasing the ability of the brain to detect dim light. Thus, rods mediate night vision; total loss of rods produces only night blindness. Because it has only one type of photopigment, rods have little if any role in color vision. Rhodopsin molecules are not permanent molecules but are continually degraded and replaced.

There are however 3 different kinds of cones, each with a different pigment, hence our trichromatic vision. One type accounts for our ability to see yellow, another for our ability to see green, and the third for violet color. It is the difference in signals the brain receives from each of these cones that allows us to perceive all possible colors. In contrast, rods contain only one type of pigment and therefore respond in the same way to different wavelengths. Cones are also responsible for our spatial resolution. This is

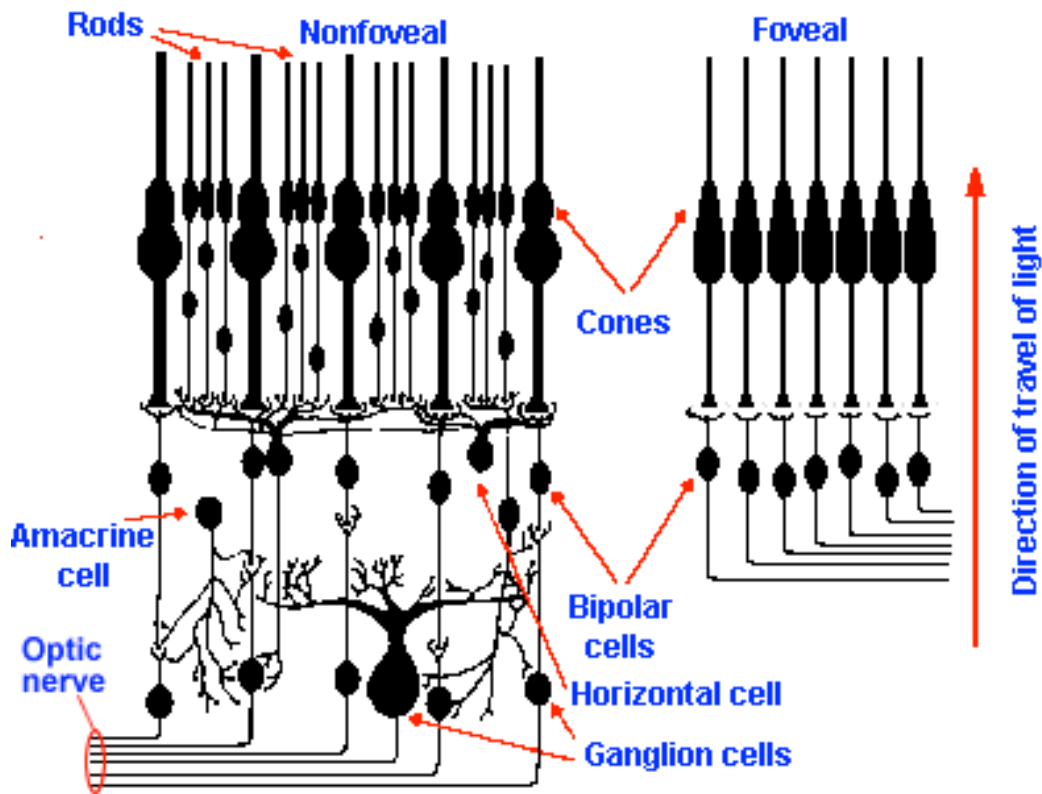


Fig. 21. Illustration depicting the anatomical arrangement of rods and cones.

because of two factors: cones are concentrated in the fovea, as shown in the above figure. where the visual image is least distorted and although rods outnumber cones by roughly 20 to 1, many rods, as previously indicated, converge on a single bipolar cell, hence the differences in the responses of the rods is averaged out in the interneuron, as shown in the above figure.

Another important point to remember is that rods and cones do not give rise to action potentials, which is also true of other sensory receptors. They respond to light through graded changes in membrane potential.

A membrane potential is the voltage difference (or electrical potential difference) between the interior and exterior of a cell. Because the fluid inside and outside a cell is highly conductive, while a cell's plasma membrane is highly resistive, the voltage change in moving from a point outside to a point inside occurs largely within the narrow width of the membrane itself. Consequently, it is common to speak of the membrane potential as the voltage across the membrane.

Action potential is a self-regenerating wave of electrochemical activity that allows excitable cells (such as muscle and nerve cells) to carry a signal over a distance. It is the primary electrical signal generated by nerve cells, and arises from changes in the permeability of the nerve cell's axonal membranes to specific ions. Thus, action potentials are pulse-like waves of voltage that travel along several types of cell membranes.

Rods respond slowly, so that the effects of all the photons absorbed during a 100 ms interval are summed together. This is why rods are able to respond to dim light, but at the same time prevents them from resolving light that is flickering faster than about 12 Hz. However, cones respond much quicker therefore they can detect flickering of light up to at least 55 Hz.

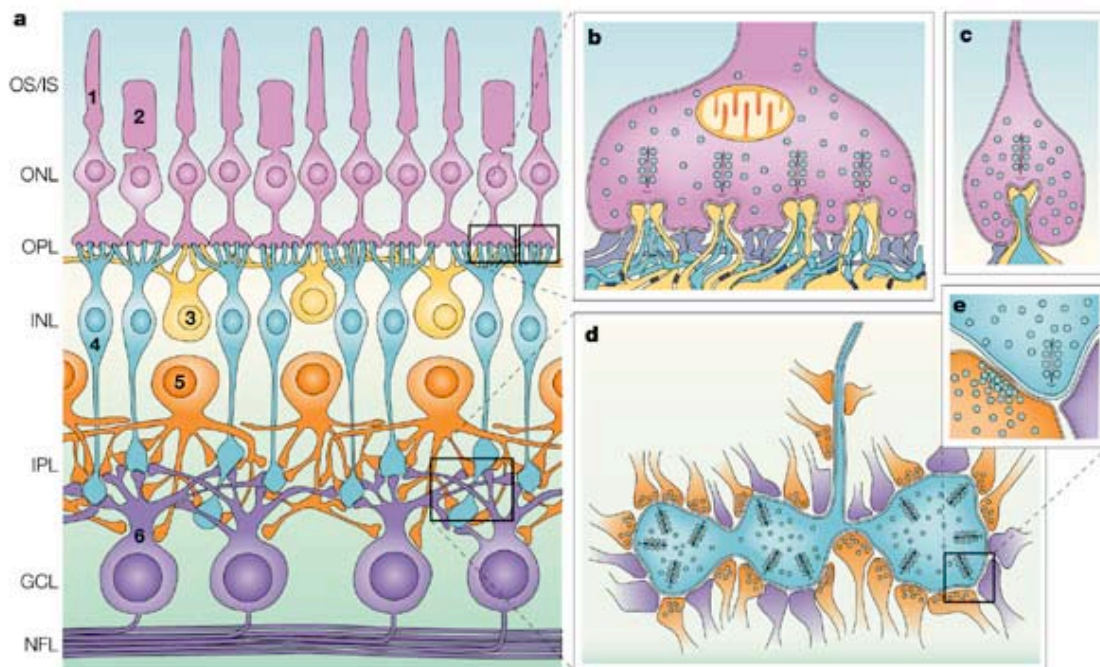
Molecular Aspects of Vision

The absorption of light by visual pigments in rods and cones triggers a cascade of events that leads to a change in ionic fluxes across the plasma membrane of these cells, and thus a change in membrane potential. Phototransduction occurs in three stages: Light activates visual pigments; the activated molecules stimulate cGMP phosphodiesterase, an enzyme that reduces the concentration of cGMP in the cytoplasm; and the reduction in cGMP concentration closes the cGMP-gated channels, thus hyperpolarizing the photoreceptor cell. This is accomplished first by the light being absorbed and thus activating rhodopsin in the rods, which causes a conformational change in the retinal component of rhodopsin (rhodopsin is composed of two components, opsin and retinal). This conformational change leads to stimulation of a G protein, which in turn activates cGMP phosphodiesterase. This enzyme catalyzes the breakdown of cGMP to 5'-GMP. As the cGMP concentration is lowered the cGMP-gated channels close, thereby reducing the inward current and causing the photoreceptor to hyperpolarize, which generates an electrical response. This electrical response is conveyed first to interneurons, which form synapses with the rods and cones, and from the interneurons to retinal ganglion cells and ultimately to the brain.

Hyperpolarization is a change in a cell's membrane potential, making it more negative. This inhibits the rise of an action potential. Depolarization makes the cell's membrane potential more positive. If the depolarization is large enough an action potential will arise.

Neurons within the Retina

The retina has three major functional classes of neurons. The rods and cones lie in the outer nuclear layer, interneurons (bipolar, horizontal, and amacrine cells) in the inner nuclear layer, and ganglion cells in the ganglion cell layer. Photoreceptors, bipolar cells, and horizontal cells make synaptic connections with each other in the outer plexiform layer. The bipolar, amacrine, and ganglion cells make contact in the inner plexiform layer. Electrical responses flow from the photoreceptors to bipolar cells to ganglion cells, as well as laterally via horizontal cells in the outer plexiform layer and amacrine cells in the inner plexiform layer.



Nature Reviews | Neuroscience

Fig. 22. In this illustration rods are labeled (1), cones (2), horizontal cells (3), bipolar cells (4), amacrine cells (5), and retinal ganglion cells (RGCs) (6). They have a laminar distribution (OS/IS), outer and inner segments of rods and cones; ONL, outer nuclear

layer; OPL, outer plexiform layer; INL, inner nuclear layer; IPL, inner plexiform layer; GCL, ganglion cell layer; NFL, optic nerve fiber layer). **b.** A cone pedicle, the synaptic terminal of the cones. Four presynaptic ribbons are apposed to the invaginating dendrites of horizontal cells (yellow) and ON (outer nuclear) cone bipolar cells (blue). This synaptic arrangement is called a 'triad'. Flat OFF cone bipolar cell dendrites form contacts at the cone pedicle base (purple). **c.** A rod spherule, the synaptic terminal of rods. The presynaptic ribbon is apposed to the invaginating axons of horizontal cells (yellow) and the dendrites of rod bipolar cells (blue). Flat OFF cone bipolar cell dendrites form contacts at the base (purple). **d.** The axon terminal of a cone bipolar (blue) contains up to 50 presynaptic ribbons, and connects to postsynaptic amacrine cell processes (orange) and RGC dendrites (purple). **e.** A magnified view of a bipolar cell ribbon synapse (blue) with an amacrine cell process (orange) and an RGC dendrite (purple). The amacrine cell provides a feedback synapse onto the bipolar cell. This synaptic arrangement is called a 'dyad'. Amacrine cells also form numerous conventional synapses throughout the IPL with RGCs and other amacrine cells (not depicted). Some amacrine cell processes reach out to the OPL and they provide synaptic contacts (interplexiform processes). (Deutsche Akademie der Naturforscher Leopoldina).

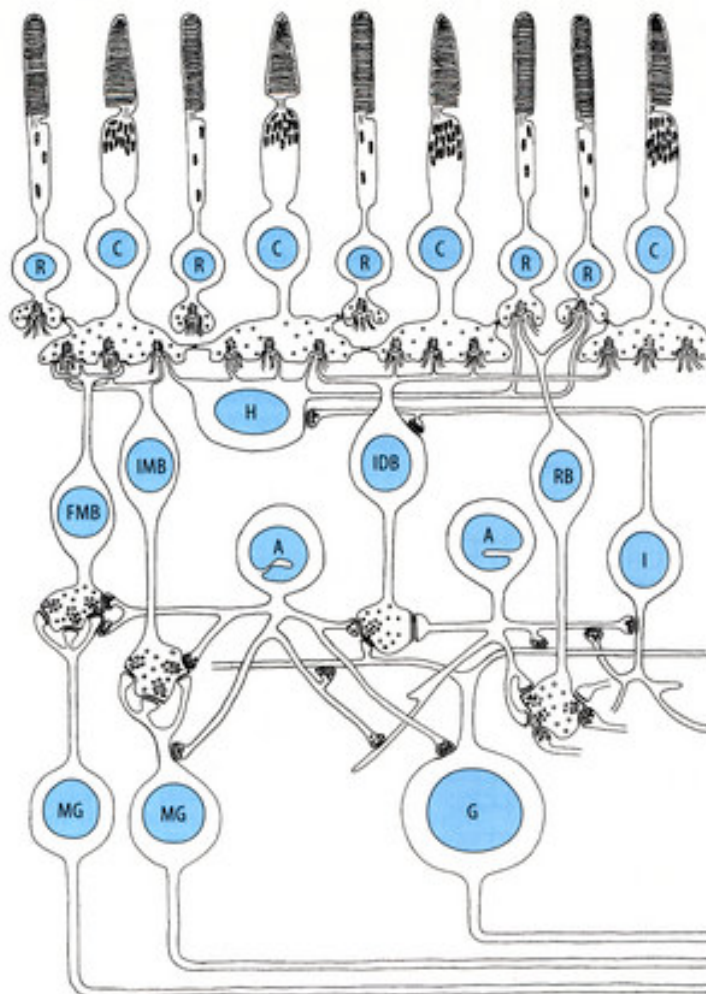


Fig. 23. This is another diagram of the synaptic organization of the primate retina. R, rod; C, cone, FMB, flat midget bipolar cell; IMB, invaginating midget bipolar cell; H, horizontal cell; IDB, invaginating diffuse bipolar cell; RB, rod bipolar cell; I, interplexiform cell; A, amacrine cell; G, ganglion cell; MG, midget ganglion cell. This diagram depicts in a very simplified fashion the cellular and synaptic organization of the primate retina. The photoreceptors, rods (R) and cones (C) provide the input to the OPL, contacting horizontal cells (H) via ribbon synapses and bipolar cells via ribbon or flat/basal synapses. One type of horizontal cell is depicted along with four bipolar cell types; flat (OFF-) and invaginating (ON-) midget bipolar cells that contact a single cone (FMB and IMB), diffuse bipolars that contact several cones (IDB), and rod bipolars (RB) that contact only rods. In the IPL the bipolar cells via ribbon synapses contact midget ganglion cells (MG), larger, diffuse ganglion cells (G) and amacrine cells (A). The rod bipolar cells contact amacrine cells that pass rod formation onto cone bipolar cell terminals and large ganglion cells. Other amacrine cells contact midget bipolar terminals, and midget and diffuse ganglion cells. Finally, a specialized type of amacrine cell, called an interplexiform cell (I), receives input in the INL and feeds information back to cells of the OPL.

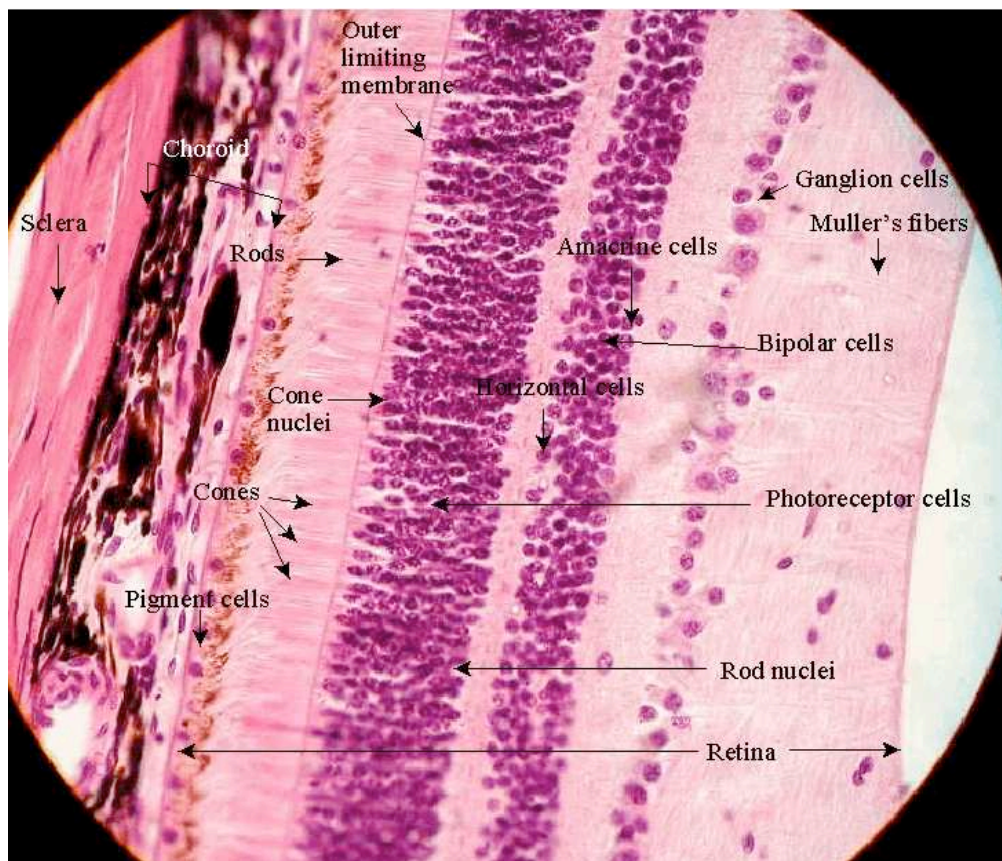


Fig. 24. This is a photomicrograph of the retina depicted in the above three illustrations

How electrical responses flow from the cones and rods is somewhat different. The base of each cone form synapses with three types of cells: horizontal cells, midget bipolar cells and the flat bipolar cells. The horizontal cells help integrate and regulate input from multiple photoreceptor cells. These cells allow us to see well under both bright and dim light. There are three types of horizontal cells: HI, HII, and HIII, which form synapses with the three types of cones; the exact function of each of these horizontal cells is open to debate. The midget bipolar and flat bipolar cells occupy a strategic position in the retina, since all signals originating in the photoreceptors and arriving at the ganglion cells must pass through them. These cells are far more numerous than the horizontal cells, hence they are involved in both direct and indirect light pathways whereas horizontal cells are part of the indirect path only.

The direct pathway is one in which a cone or rod makes a direct connection with a bipolar cell, which in turn makes a direct connection with a ganglion cell. In the indirect (lateral) pathway, the activated cone transmits to ganglion cells lateral to them through horizontal cells or amacrine cells.

The base of each rod form synapses with the horizontal and flat bipolar cells. The synapses formed between the horizontal cells and the cones are via dendrites from the horizontal cells, whereas the synapses formed between the horizontal cells and rods are through the axons of the former. Hence, horizontal cells receive impulses from one group of cone cells and transmit their impulses to rods and cones of another region within the retina. The midget bipolar and flat bipolar cells transmit impulses from the rods and cones to the ganglion cells of the retina and from the latter ultimately to the visual centers in the brain.

Whereas the horizontal and bipolar cells are in the outer plexiform layer, the amacrine cells are in the inner plexiform layer. Like the horizontal cells, the amacrine cells function as interneuron's affecting the output of the bipolar cells of the plexiform layer. Amacrine cells are responsible for approximately 70% of the impulses to the ganglion cells with the bipolar cells accounting for the other 30%.

The retinal ganglion cells are located in the ganglion cell layer. They receive impulses from the amacrine and bipolar cells. The ganglion cells then transmit impulses via their axons, which form the optic nerve, chiasm and tract, to the thalamus, hypothalamus and midbrain.

Retinal ganglion cells vary significantly in terms of their size, connections, and responses to visual stimulation, but they all share the defining property of having a long axon that extends into the brain. These axons form the optic nerve, optic chiasm and optic tract. A small percentage of retinal ganglion cells contribute little or nothing to vision, but are themselves photosensitive; their axons form the retinohypothalamic tract and contribute to circadian rhythms and pupillary light reflex, the resizing of the pupil.

There are approximately 1.2 to 1.5 million retinal ganglion cells in the human retina. With about 125 million photoreceptors per retina, on average each retinal ganglion cell receives inputs from about 100 rods and cones. However, these numbers vary greatly among individuals and as a function of retinal location. In the fovea (center of the retina), a single ganglion cell will communicate with as few as five photoreceptors. In the extreme periphery (ends of the retina), a single ganglion cell will receive information from many thousands of photoreceptors.

Based on their projections and functions, there are at least five main classes of retinal ganglion cells: Midget cell (Parvocellular, or P pathway; B cells); Parasol cell (magnocellular, or M pathway; A cells); Bistratified cell (Koniocellular, or K pathway); Photosensitive ganglion cells and other ganglion cells projecting to the superior colliculus for eye movements (saccades). The midget, parasol and bistratified ganglion cells project to the lateral geniculate nucleus (thalamus), which is the principal subcortical center for processing visual information that is then sent to the visual cortex surrounding the calcarine fissure. The calcarine fissure is located on the medial surface of the posterior aspect of the occipital lobe. The lateral geniculate nucleus (LGN) receives approximately 90% of the axons of the retinal ganglion cells.

The midget retinal ganglion cells specifically project to the parvocellular layers of the lateral geniculate nucleus as previously stated. These cells are known as midget retinal ganglion cells, based on the small sizes of their dendritic trees and cell bodies. About 80% of all retinal ganglion cells are midget cells in the parvocellular pathway. They receive inputs from relatively few rods and cones. In many cases, they are connected to midget bipolars, which are linked to one cone each.

Parasol retinal ganglion cells project to the magnocellular layers of the lateral geniculate nucleus. These cells are known as parasol retinal ganglion cells, based on the large sizes of their dendritic trees and cell bodies. About 10% of all retinal ganglion cells are parasol cells, and these cells are part of the magnocellular pathway. They receive inputs from many rods and cones.

Bistratified retinal ganglion cells project to the koniocellular layers of the lateral geniculate nucleus. Bistratified retinal ganglion cells have been identified only relatively recently. Koniocellular means “cells as small as dust”; their small size made them hard to find. About 10% of all retinal ganglion cells are bistratified cells, and these cells go through the koniocellular pathway. They receive inputs from intermediate numbers of rods and cones. They are involved in color vision. They have very large receptive fields that only have centers (no surrounds) and are always ON to the blue cones and OFF to both the red and green cones.

Photosensitive ganglion cells, including, but not limited to the giant retinal ganglion cells, contain their own photopigment, melanopsin, which makes them respond directly to light, even in the absence of rods and cones. They project to, among other areas, the suprachiasmatic nucleus (SCN) via the retinohypothalamic tract for setting and maintaining circadian rhythms. Other retinal ganglion cells projecting to the lateral geniculate nucleus (LGN) include cells making connections with the Edinger-Westphal nucleus (EW), for control of the pupillary light reflex, and giant retinal ganglion cells.

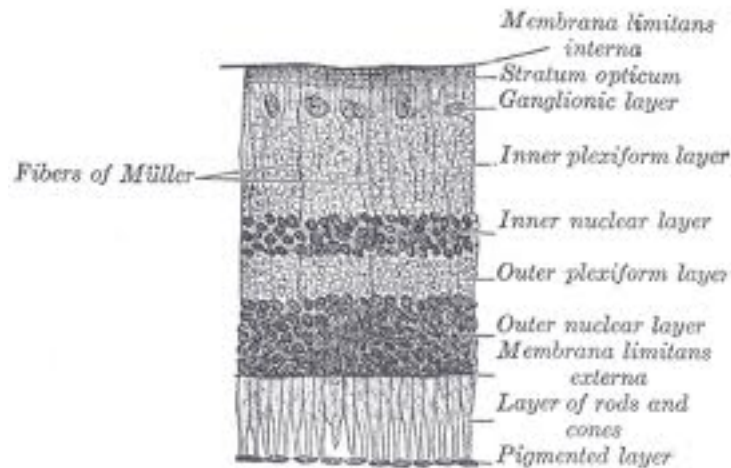


Fig. 25. This diagram shows a cross-section of retinal layers. The area labeled “Ganglionic layer” contains retinal ganglion cells.

The M cells and P cells form the two segregated major pathways in which visual information is conveyed from the retina to the visual cortex. Each of these cells transmits somewhat different information to different layers of the LGN. The axons of the M cells as indicated above, project to the magnocellular layers of the LGN (the M pathway), whereas the axons of the P cells project to the parvocellular layers (the P pathway). These two pathways then continue from these separate layers of the LGN to separate layers in the primary visual cortex (the M pathway to layer 4C α and the P pathway to 4C β).

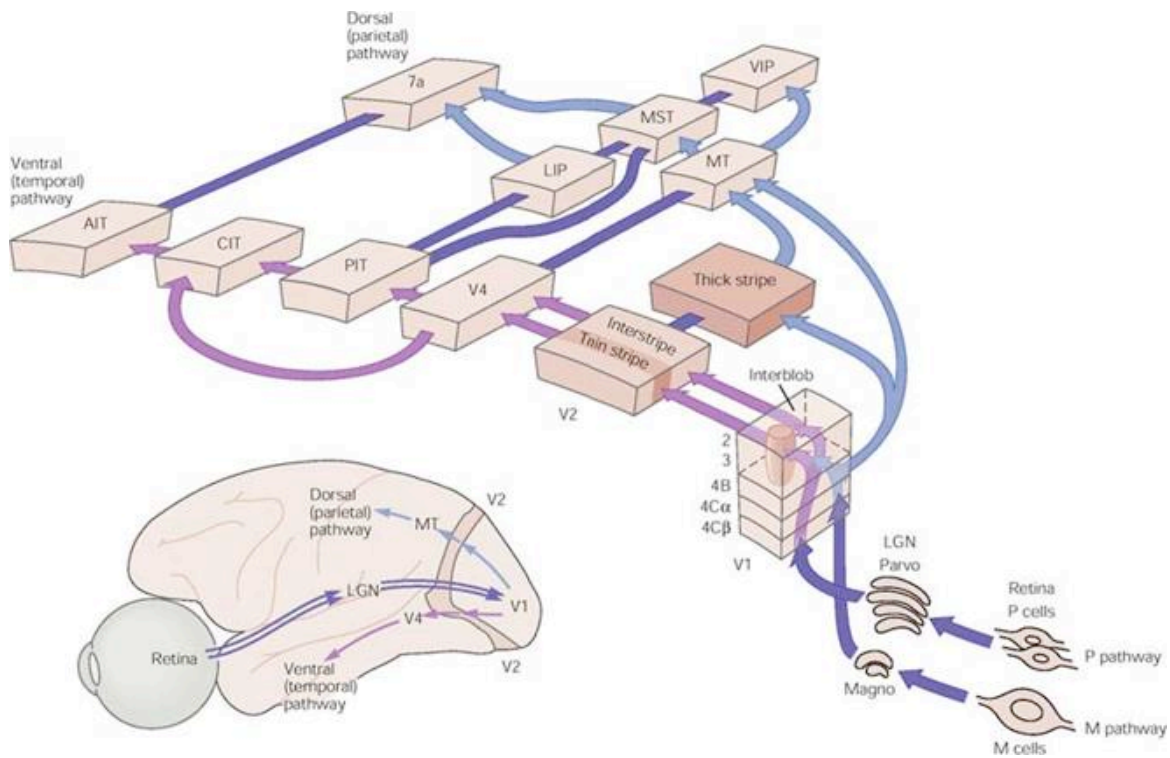


Fig. 26. This diagram represents the magnocellular (M) and parvocellular (P) pathways from the retina project through the lateral geniculate nucleus (LGN) to V₁ (the primary visual cortex). Separate pathways to the temporal and parietal cortices course through the extrastriate cortex beginning in V₂. The connections shown in the diagram are based on established anatomical connections, but only selected connections are shown and many cortical areas are omitted. Note the cross connections between the two pathways in several cortical areas. The parietal pathway receives input from the M pathway but only the temporal pathway receives input from both the M and P pathways. (Abbreviations: AIT, anterior inferior temporal area; CIT, central inferior temporal area; LIP, lateral intraparietal area; Magno, magnocellular layers of the lateral geniculate nucleus; MST, medial superior temporal area; MT, middle temporal area; Parvo, parvocellular layers of the lateral geniculate nucleus; PIT, posterior inferior temporal area; VIP, ventral intraparietal area.) (Based on Merigan and Maunsell 1993.)

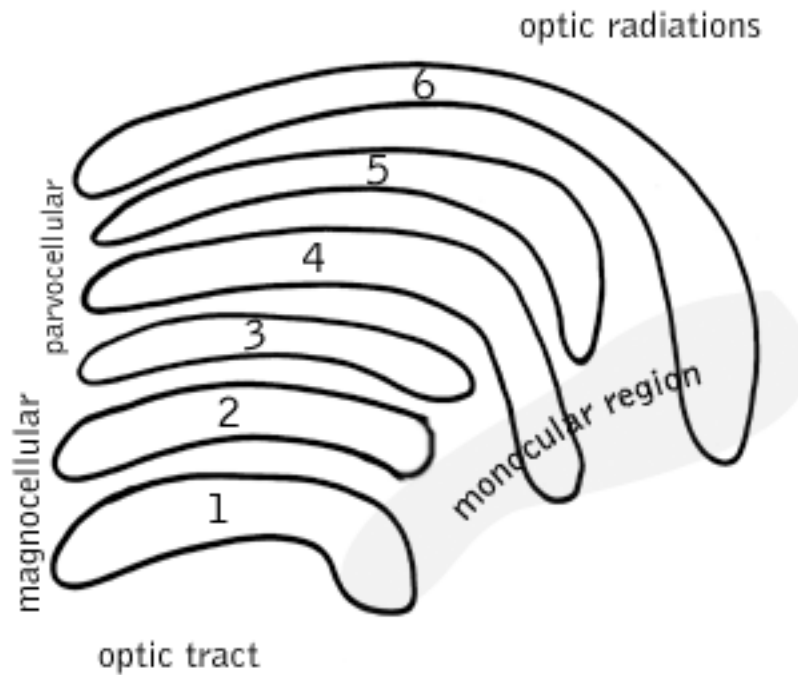


Fig. 27. This is a schematic diagram of the primate lateral geniculate nucleus. In most primates, including humans, it has six layers of cell bodies with layers of neuropil between, in an arrangement much like a layer cake, with cell bodies of LGN neurons as the “cake” and the neuropil as the “icing”. These six layers contain two types of cells. The cells in layers 1 and 2 are large, or magnocellular (M); others in layers 3, 4, 5, and 6 are smaller, or parvocellular (P). Between each of the M and P layers lies a zone of very small cells: the interlaminar, or koniocellular (K), layers. K cells are functionally and neurochemically distinct from M and P cells and provide a third channel to the visual cortex. The magnocellular, parvocellular, and koniocellular layers of the LGN correspond with the similarly-named types of ganglion cells.

Magnocellular cells have large cell bodies, use a relatively short time to process information, and are part of a visual processing system that tells the brain where something is. This system operates quickly but without much detail. Being located in layers 1 and 2 of the LGN, they are immediately next to the incoming optic tract. M cells are the retinal ganglion cells that project their axons to the magnocellular layers of the LGN.

Parvocellular cells have small cell bodies, use a relatively long time to process information, and are part of a visual processing system that tells the brain what something is. This system operates more slowly and with lots of information about details. For example, these cells carry color information while magnocellular cells do not. P cells of the retinal ganglion cells that project their axons to the parvocellular layers of the LGN. Koniocellular cells have very small bodies and are located in between the layers. They are also part of the system that tells the brain what something is; usually, their principle role is to determine color. K cells are the retinal ganglion cells that project their axons to the koniocellular layers of the LGN.

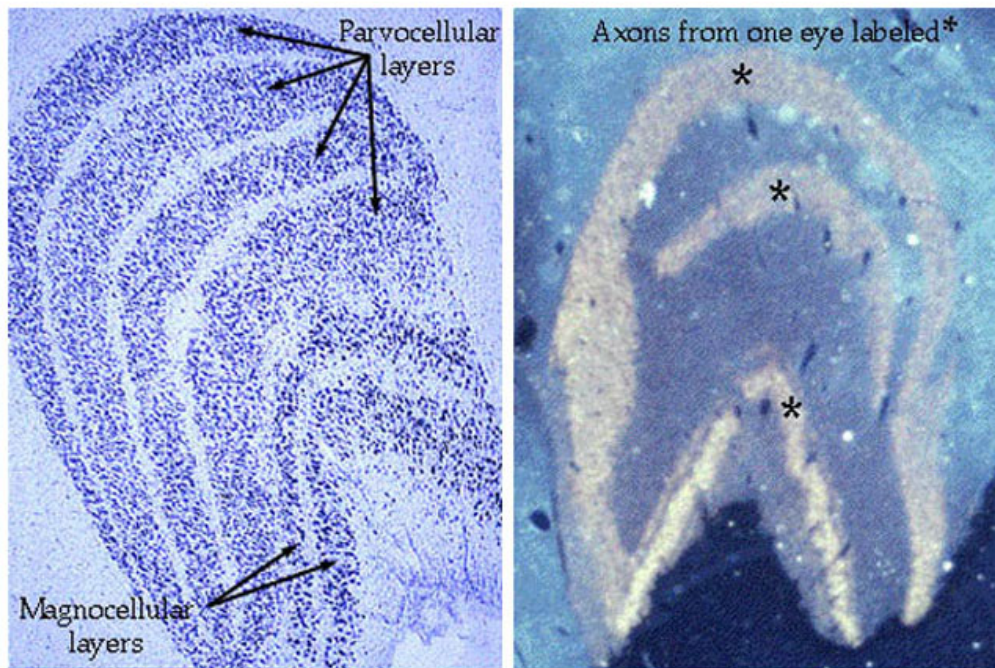


Figure 11. The projections of the small (P cells), and large (M cells) ganglion cells from the two eyes to parvocellular and magnocellular layers of the LGN respectively. Each eye projects to alternating layers as seen in the autoradiogram (right).

Fig. 28. The above primate LGN microphotograph was excerpted from Webvision.

There are some retinal ganglion cells, which in addition to sending axons to the lateral geniculate nucleus, also send axons to the superior colliculus, which is the visual reflex center. The superior colliculus along with the inferior colliculus occur on the dorsal surface of the midbrain. These two structures collectively form a part of the brainstem called the tectum.

Ganglion cells also terminate in the pretectal region, which is just anterior to the superior colliculus. The pretectal region is an important visual reflex center involved in pupillary eye reflexes, in which the pupil constricts in response to light shining on the retina.

As stated above, in addition to the M & P retinal ganglion cells, there are also bistratified retinal ganglion cells, which are referred to as koniocellular cells. These cells constitute 10% of the retinal ganglion cells and form what is called the k-pathway. They receive inputs from a variable number of rod & cones. They project their axons to similarly named cells in the LGN.

The photosensitive ganglion cells differ from the other four classes of retinal ganglion cells in that they are intrinsically photosensitive. Thus, there are three cells within the retina that are photoreceptors; the others are the rods and cones. The pigment within these ganglion cells is called **melanopsin**. These cells play a major role in synchronizing circadian rhythms and regulating pupillary light response.

Optic Nerves (CNII)

There is a fundamental point that needs to be clarified, since the optic nerves arise as an outpouching of the **diencephalon** they are technically not a nerve, but a tract, due to the fact that all structures composing the optic system are within the CNS.

The diencephalon is a nuclear complex located at the rostral end of the brainstem. It is regarded as the key to the understanding of the organization of the **central nervous system (CNS)**. Caudally the diencephalon appears continuous with the tegmentum of the midbrain; the posterior commissure is the junctional zone between the diencephalon and the mesencephalon. The rostral boundary of the diencephalon is near the interventricular foramen with portions of the hypothalamus extending almost to the lamina terminalis. Laterally the posterior limb of the internal capsule, the tail of the caudate nucleus and the stria terminalis bound it. The third ventricle separates the diencephalon into two symmetrical halves, except in the region of the interthalamic adhesion, where the medial surfaces of the thalami may be in continuity. The diencephalon consists of four major parts: the **epithalamus**, the **thalamus**, the **hypothalamus** and the **subthalamus**, or the **ventral thalamus**. The medial and lateral geniculate nuclei constitute distinctive subdivisions of the thalamus, referred to as the **metathalamus**.

From an anatomical perspective, nerves lie within the **peripheral nervous system (PNS)**. To further emphasize this point, the optic nerves are ensheathed by the dural mater, arachnoid membrane and pia mater, whereas nerves are ensheathed in the epineurium, perineurium and endoneurium. The optic nerves are composed of the axons from the retinal ganglion cells, which collect into a bundle in the posterior part of the eye called the **optic disc**. The axons extend from the optic disc of each eye, as the optic

nerve to the **optic chiasm**. The intracranial part of the optic nerve measure 1 cm in length. The chiasm lies in front of the stalk for the hypothalamus over the diaphragma sellae.

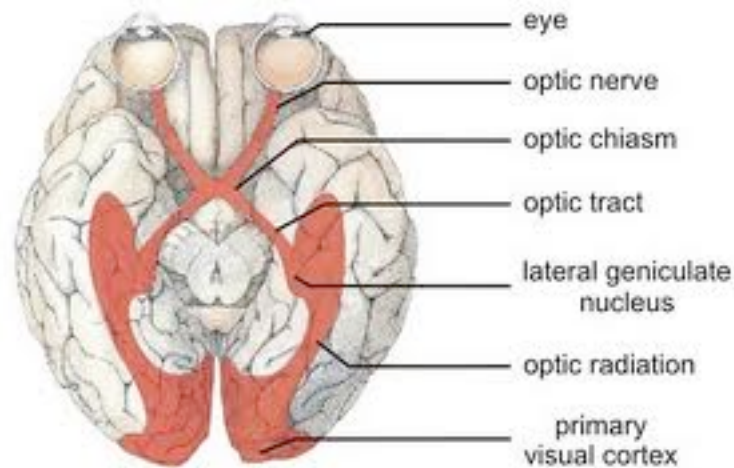


Fig. 29. Illustration depicting the fundamental anatomy of the visual system.

Optic Chiasm and Optic Tract

In the optic chiasm the axons from the retinal ganglion cells from the nasal half of each retina cross to the opposite side (decussate), thus travel in the opposite optic tract, which as previously indicated, approximately 90% of the axons project to the lateral geniculate nucleus. Consequently, due to the process of decussation, the left half of the field of vision is perceived by the right cerebral hemisphere and the right half by the left cerebral hemisphere. You must keep in mind that the axons from the temporal side of the retinal ganglion cells do not decussate in the optic chiasm, but precede directly through the chiasm into the optic tract on the same side as they exited in their optic nerves. Thus, axons from the left half of each retina (the temporal hemiretina of the left eye and the nasal hemiretina of the right) project in the left optic tract, which thus carries a complete representation of the right hemifield of vision; fibers from the right half of each retina (the nasal hemiretina of the left eye and the temporal hemiretina of the right eye) project in the right optic tract, which carries a complete representation of the left hemifield of vision. This separation of the right visual hemifield into the left optic tract and the left

visual hemifield into the right optic tract is maintained in all axon projections to the subcortical visual nuclei.

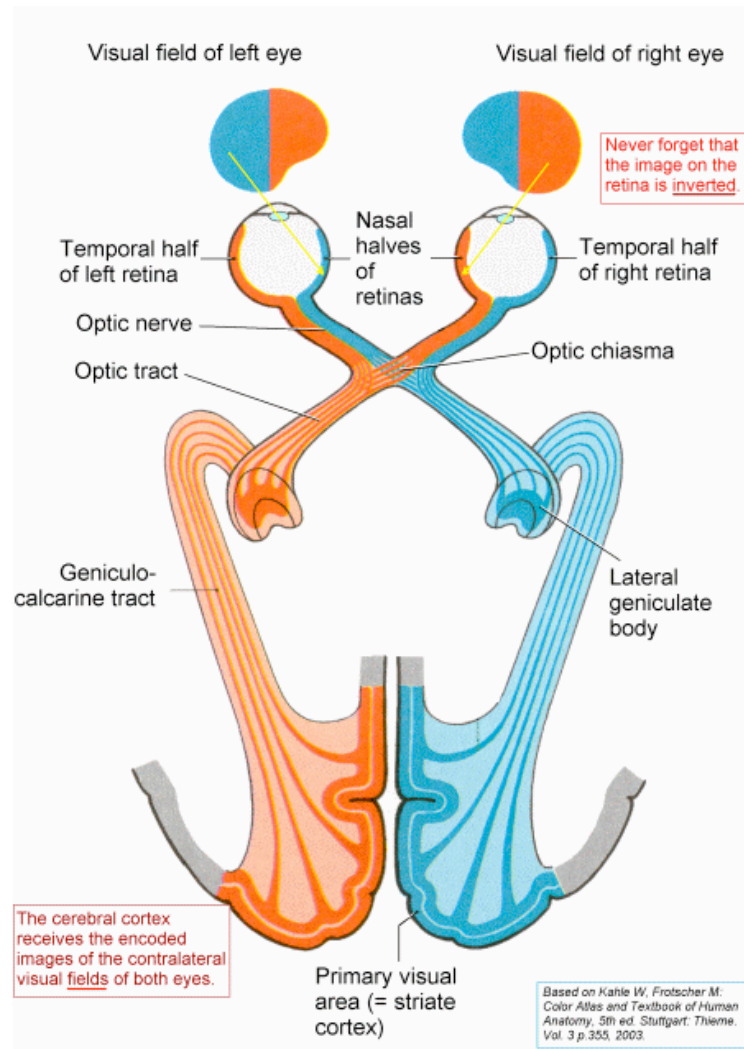


Fig. 30. This illustration depicts the projections of the hemifields.

There is another aspect of how visual information is transmitted from the retina to the visual cortex that we must keep in mind. The lens of the eye, just as is true in a camera, projects an inverted image on the retina. Thus, the upper half of the visual field projects onto the inferior half of the retina, while the lower half of the visual field projects onto the superior half of the retina. Consequently, damage to the inferior half of the retina of one eye causes a monocular deficit in the upper half of the visual field.

The optic tracts extend outward and posteriorly, encircling the hypothalamus and the rostral portions of the crus cerebri.

The crus cerebri is located on the anterior surface of the cerebral peduncle, which contains the motor tracts: corticospinal tract, corticobulbar tract, corticopontine tract/ frontopontine fibers/temporopontine fibers. The cerebral peduncle includes everything in the mesencephalon except the tectum. It includes the midbrain tegmentum, crus cerebri and pretectum. By this definition, the cerebral peduncles are also known as the basis pedunculi, while the large ventral bundle of the efferent fibers is referred to as the crus cerebri or pes peduncle. The fibers in the most lateral part of the central region are concerned with the lower extremity; the middle region are fibers concerned with the upper extremity; and the most medial fibers of the central region are concerned with the musculature of the face, pharynx and larynx. The extreme medial portions of the crus cerebri contain frontopontine fibers, while the corticopontine fibers from the temporal, parietal and occipital cortices are located laterally.

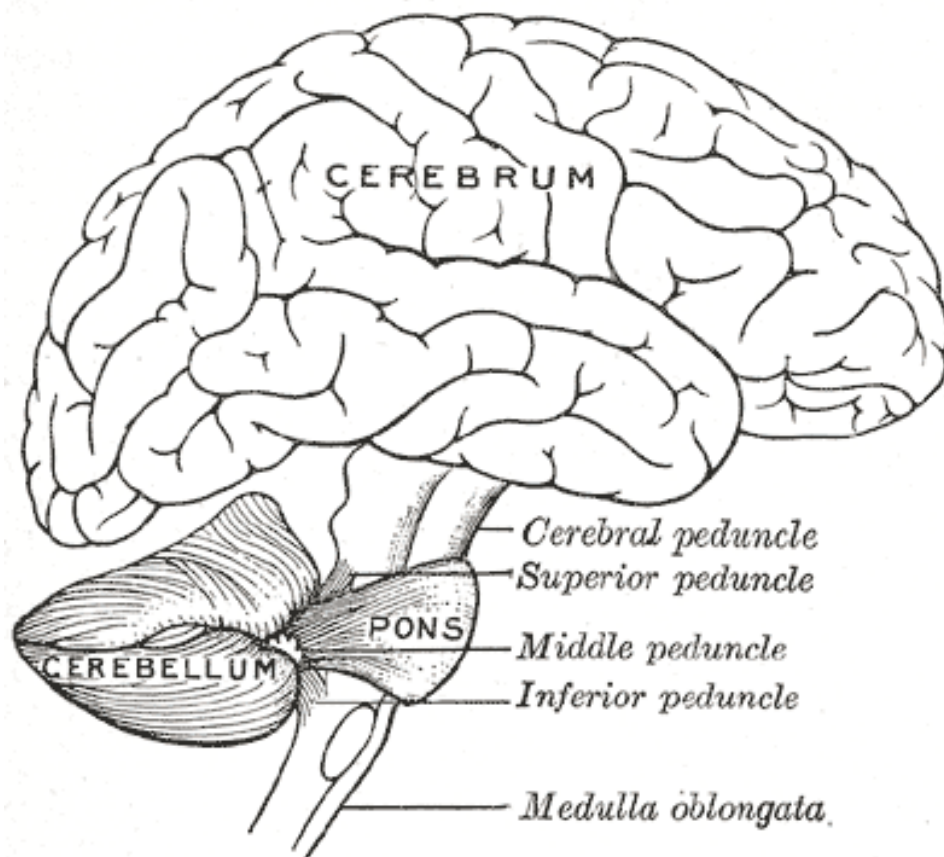


Fig. 31. The above illustration is of the human brain, with the midbrain located at the level marked 'cerebral peduncle'. From Henry Gray, *Anatomy of the Human Body*, 1918, Fig 677.

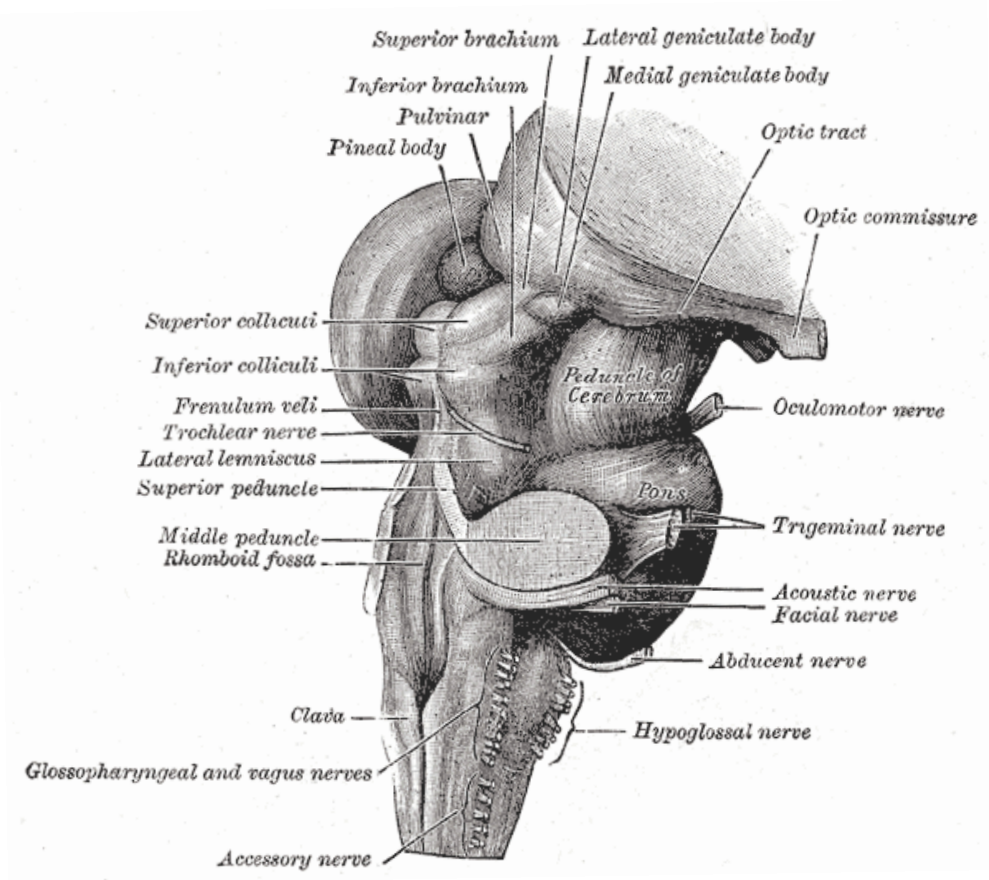


Fig. 32. This illustration is a closeup of the mid- and hind-brain; the midbrain is the area above the pons. From: Henry Gray, *Anatomy of the Human Body*, 1918, Fig 681

As previously indicated approximately 90% of its axons terminate in the lateral geniculate nucleus with a small percentage continuing as the brachium of the superior colliculus to the superior colliculi and the pretectal area.

The lateral geniculate nuclei give rise to the geniculocalcarine tract, which forms the last relay to the visual cortex, as shown in Fig. 30.

The superior colliculus is concerned with the perception of movement within the visual fields and with the coordination of eye and head movements. Before we proceed, it is important that we have some understanding of the fundamental anatomy and function of

the superior colliculus. A major component of the midbrain are paired structures called the tectum. In mammals this structure is more commonly called the superior colliculus. The superior colliculus (tectum) is a layered structure, with the number of layers varying according to species. The superficial layers are sensory related, and receive input from the eyes as well as other sensory systems. The deep layers are motor related, capable of activating eye movements as well as other responses. There are also intermediate layers, with multi-sensory cells and motor responses.

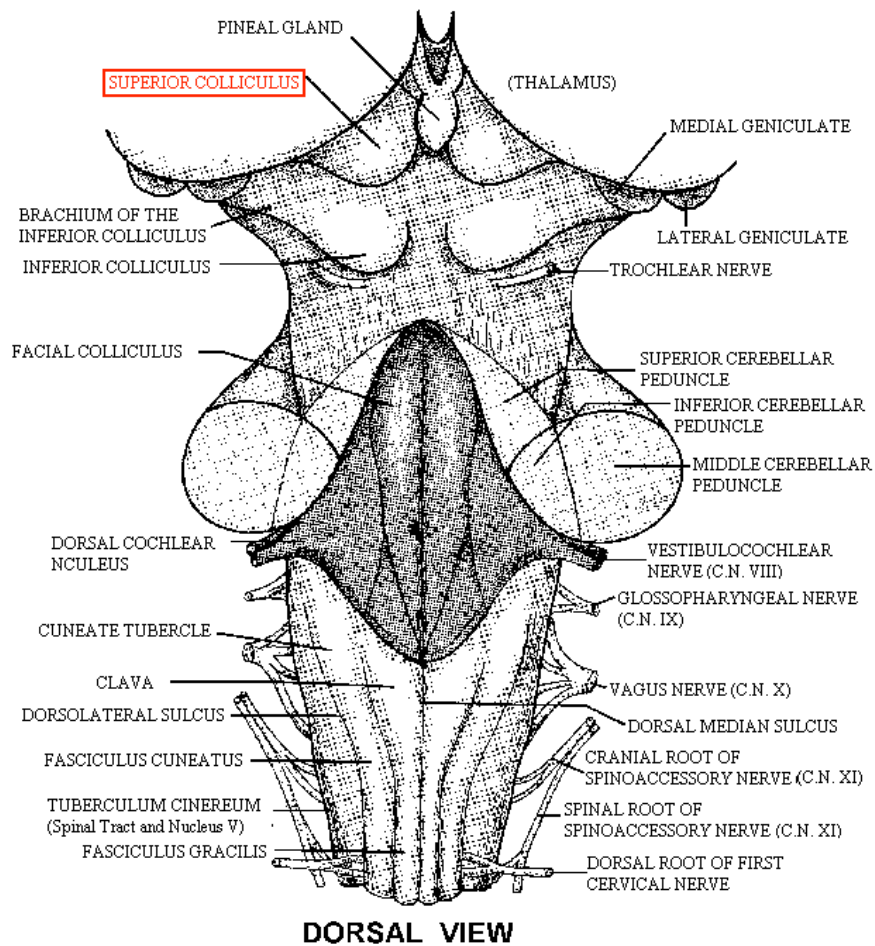


Fig. 33. This is an illustration of the dorsal view of the brain stem showing the anatomic location of the superior colliculi and its' relation to some of the other structures of the brain stem.

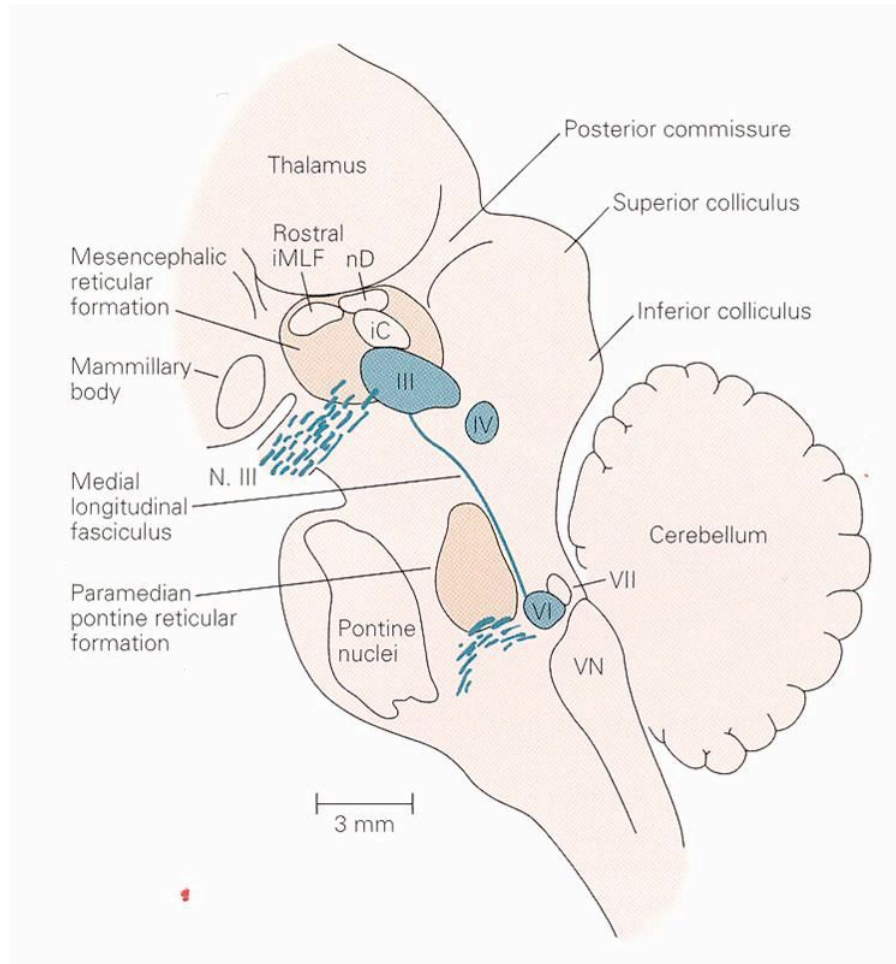


Fig. 34. This is a sagittal view of the brain stem, thalamus and cerebellum.

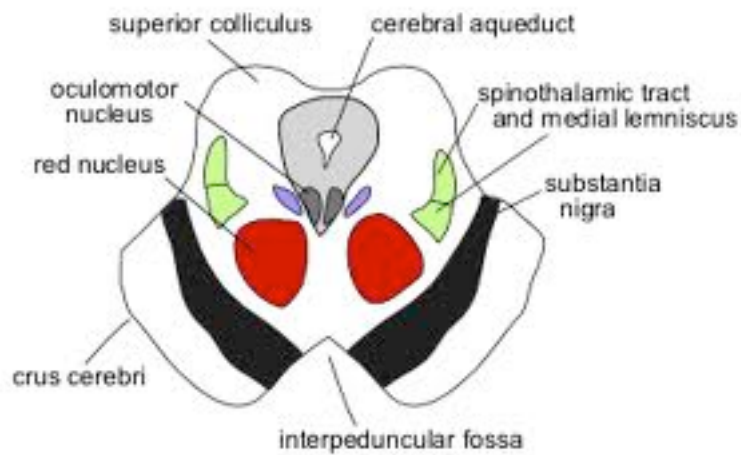


Fig. 35. This is an illustration of a cross-section of the midbrain.

As shown above, the two superior colliculi sit below the thalamus and surround the pineal gland in the midbrain of vertebrate brains. It comprises the caudal aspect of the midbrain, posterior to the periaqueductal gray and immediately superior to the inferior colliculus. The inferior and superior colliculi are known collectively as the corpora quadrigemina.

The microstructure of the superior colliculus shows a clear distinction between superficial layers, which receive input primarily from the visual system and show primarily visual responses, and deeper layers, which receive many types of inputs and project to numerous motor-related areas. The distinction between these two zones is so clear and consistent across species, that some anatomists have suggested they should be considered separate brain structures.

There are seven microscopic layers to the superior colliculi. The top three layers are called *superficial*: Lamina I, II and III. They are followed by two *intermediate* layers: Lamina IV and Lamina V. The last two are the *deep layers*: Lamina VI and Lamina VII.

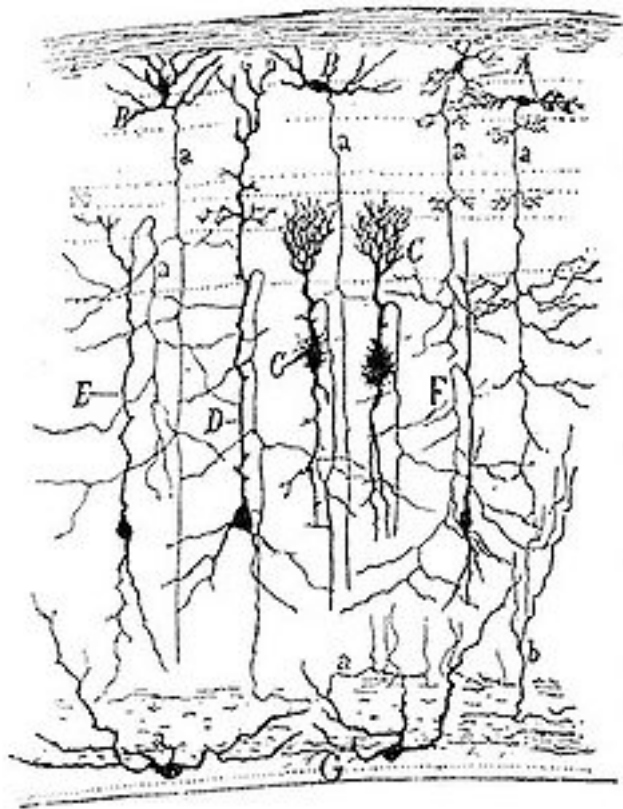


Fig. 36. The above drawing was by Ramon y Cajal of several types of neurons in the optic tectum (superior colliculus) of a sparrow.

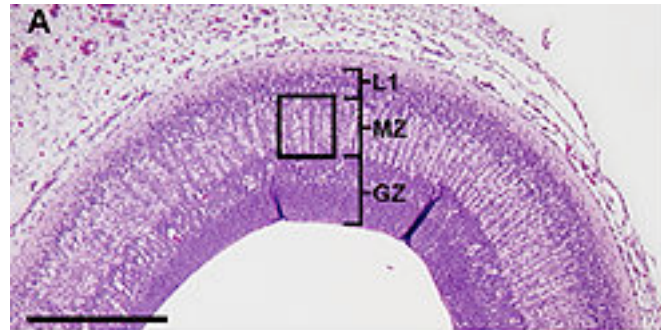


Fig. 37. This is a photomicrograph of a chicken optic tectum (superior colliculus) showing the generative zone (GZ), the migrating zone (MZ) and the first neuronal lamina (LI). From Catharp et al, 2007.

The general function of the tectal system (superior colliculi) is to direct behavioral responses toward specific points in egocentric (“body-centered”) space. Each layer of the tectum contains a topographic map of the surrounding world in the retinotopic coordinates, and activation of neurons at a particular point in the map evokes a response directed toward the corresponding point in space. In primates, the tectum (superior colliculus) has been studied mainly, with respect to its role in directing eye movements. Visual input from the retina, or “command” input from the cerebral cortex, create a “bump” of activity in the tectal map, which, if strong enough, induces a saccadic eye movement.

The pretectal area, as previously indicated, is concerned with the papillary light reflex. In addition, some of the photosensitive retinal ganglion cells give rise to the retinohypothalamic tract which projects directly to the suprachiasmatic nuclei through the optic nerve and chiasm. These nuclei are involved in the regulation of circadian rhythm. The suprachiasmatic nuclei are located in the anterior hypothalamus, dorsal and superior to the optic chiasm, on either side of the third ventricle.

Lateral Geniculate Nucleus (LGN)

The LGN is a thalamic relay nucleus for the visual system, lying rostral and lateral to the medial geniculate nucleus (MGN), lateral to the posterior part of the crus cerebri and ventral to the pulvinar. The LGN is the principal subcortical structure that carries visual information to the visual cortex. Destruction of the pathway to and from the LGN leads to a complete loss of vision, although some minimal detection and movement toward objects is still possible. This residual vision is mediated through the SC (superior colliculus) and is called blindsight vision. As previously discussed, ganglion cells in the retina project in an orderly manner to finite areas in the LGN; thus, in each LGN there is a retinotopic representation of the contralateral half of the visual field (see Fig. 28).

The LGN has a laminated arrangement consisting of 6 cellular layers, each separated by a fiber layer. The cellular layers are numbered 1 through 6 and are divided into two broader divisions: the ventral, which consist of layers 1 and 2, and the dorsal, which consist of layers 3 to 6 (see Fig. 27).

The ventral subdivisions consist of large cells and are therefore referred to as the magnocellular layer, which receive their primary input from the M ganglion cells of the retina. The dorsal subdivision consist of small cells and are thus referred to as the parvocellular layers, which receive their input from the P ganglion cells of the retina. The M cells respond weakly to color, whereas the P cells respond strongly. M cells are better in determining luminance contrast (measure of the difference between the brightest and darkest parts) than P cells. M cells are better at determining temporal resolution. The axons that project from the LGN go to the visual cortex with both magnocellular layers and parvocellular layers sending their axons to layer 4 of the VI of the visual cortex.

As previously indicated, there are cells within the retina called bistratified ganglion cells, which are also referred to as koniocellular cells. These cells, as is true to the M & P retinal ganglion cells, project to similarly named cells in the LGN. The koniocellular cells in the LGN are located between the layers formed by the M & P cells. It is believed these cells form a third pathway to the visual cortex. Their precise role in vision is unclear, although it is thought they may play a role in integrating somatosensory system

proprioceptive information with visual perception and may also be involved in color perception.

The projections from the retina to the LGN are very precise with each individual layer in the nucleus receiving input from one eye only. Crossed fibers of the optic tract (fibers from the contralateral nasal hemiretina) terminate in layers 1, 4 and 6, while uncrossed fibers (fibers from the ipsilateral temporal hemiretina) terminate in layers 2,3 and 5. Thus, although one LGN carries complete information about the contralateral visual field, the inputs from each eye remain segregated.

The actual function of the LGN is unknown, although it is regarded as the principal subcortical site for processing visual information. Only 10 to 20% of the presynaptic connections onto the geniculate relay cells come from the retina. The majority of inputs come from other regions and many of these, particularly those from the reticular formation in the brainstem and the cortex, are feedback inputs. It is believed these feedback inputs to the LGN may control the flow of information from the retina to the cortex, perhaps helping the visual system to focus its attention on the most important information.

Superior Colliculus

The superior colliculus is a laminated structure consisting of alternating neuronal layers and axonal layers. The outer layers receive information from the retina and visual cortex. The cells in the superficial layer in turn project through the pulvinar nucleus of the thalamus to a broad area of the cerebral cortex, thus forming an indirect pathway from the retina to the cerebral cortex. The middle and deeper layers receive inputs from multiple areas of the brain, which include both motor and sensory. The sensory inputs are visual, auditory and somatosensory; hence the superior colliculus plays a role in orienting the head and eyes to all types of sensory stimuli. This is accomplished through impulses traveling through the tectospinal tract to the neurons in the cervical spinal canal. This tract is important in reflex turning of the head in response to visual, auditory and somatosensory stimuli. It also projects to the cerebellum via the tectopontine tract, for further processing of eye-head control. For example, a flash of light to your eyes from

the right will cause you to turn your head to the right. The superior colliculus has three primary functions: receives neural impulses directly from the retina; it is involved in hand-eye coordination; and in saccadic eye movement.

Saccadic eye movements are quick simultaneous movements of both eyes in the same direction. These movements are based on neuronal discharges in the intermediate and deeper layers of the superior colliculus. As an example, cells responding to visual stimuli in the left visual field will discharge vigorously before a leftward directed saccade, which can occur within 200 milliseconds of the initiating stimulus and last approximately 20 to 200 milliseconds. Although the superior colliculus receives direct retinal input, it is thought these movements are controlled by inputs from the cerebral cortex that send impulses to the intermediate layers, which in turn cause the deeper layers to discharge rapidly, thus initiating the saccadic eye movement (see Fig. 38 and 39).

Pretectal Area

As indicated above, although 90% of the retinal ganglion cells project to the lateral geniculate nucleus with some being projected to the superior colliculus, others are projected to an area just rostral to the superior colliculus where the midbrain fuses with the thalamus. This region is called the **pretectal area**. Thus, the pretectal area receives binocular input from the retinal ganglion cells.

The pretectal area is a region of neurons found between the thalamus and midbrain.

The cells in the pretectal area project bilaterally to neurons within a structure called the **Edinger-Westphal nucleus (accessory oculomotor nucleus)**. This nucleus occurs within the midbrain at the level of the superior colliculus and immediately adjacent to the **oculomotor nucleus (CNIII)**, which is located just anterior to the cerebral aqueduct.

The Edinger-Westphal nucleus contains preganglionic parasympathetic neurons, which sends axons with **oculomotor nerve (CNIII)** to innervate the **celiac ganglion**, within which it forms synapses with postganglionic neurons. These postganglionic neurons in turn innervate the smooth muscle of the papillary sphincter causing it to contract.

Pupillary dilatation occurs through a sympathetic pathway with innervations of the **papillary radial iris muscles**.

To put this in a more understandable manner, the pretectum, after receiving binocular input, outputs to the Edinger-Westphal nucleus in the midbrain, to the cilio-spinal nucleus (Budge), which is located in the VIII cervical and I, II thoracic vertebral segments, and to the nucleus of the posterior commissure. The Edinger-Westphal nucleus projects onto the ciliary ganglion, whose output controls pupillary constriction (miosis). The Edinger-Westphal nucleus controls the pupillary sphincter muscle (used to reduce the exposure of the retina to bright light) and the ciliary muscles (used for eye focusing and accommodation). The **Cilio-Spinal Nucleus** projects onto the superior cervical ganglion, and controls the pupillary dilator muscle (used in situations of near dark), to increase the exposure of the retina.

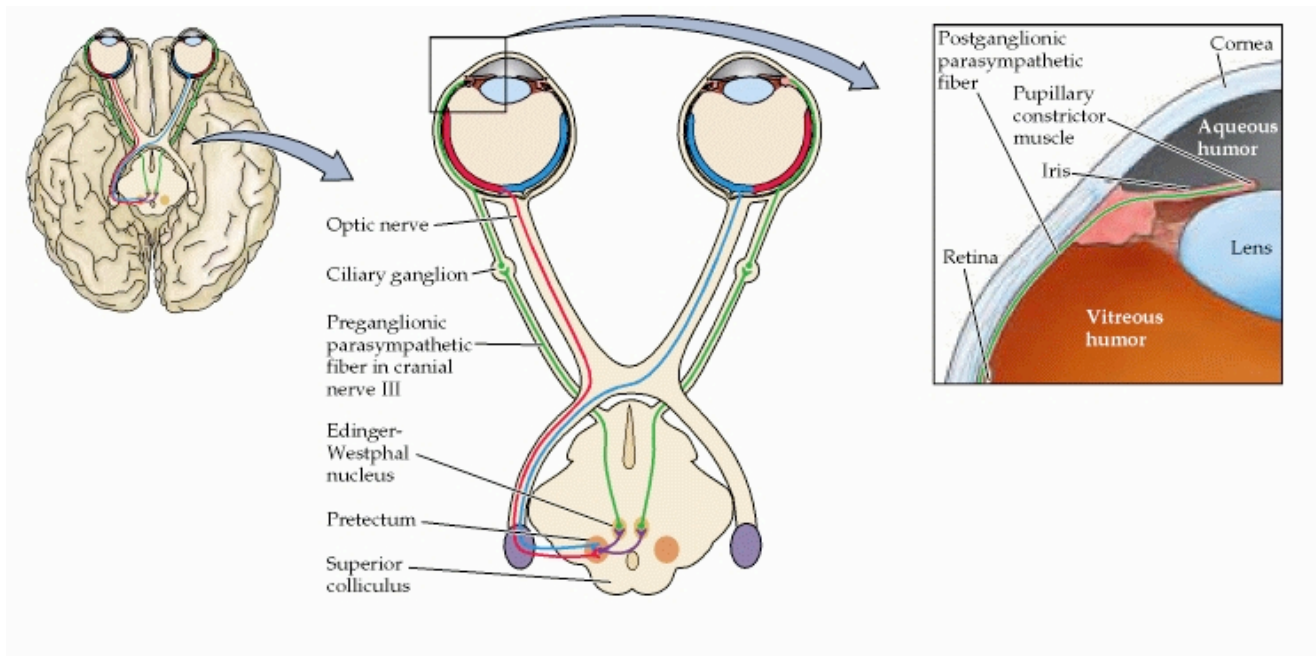


Fig. 38. This illustration shows the circuitry responsible for the pupillary light reflex. This pathway includes bilateral projections from the retina to the pretectum and projections from the pretectum to the Edinger-Westphal nucleus, which send their axons via the oculomotor nerve to terminate on neurons in the ciliary ganglion. Neurons in the ciliary ganglion innervate the constrictor muscle in the iris, which decreases the diameter of the pupil when activated. Notice that the afferent axons activate both Edinger-Westphal nuclei via the neurons in the pretectum. Thus, shining a light in the eye leads to an increase in the activity of the pretectal neurons, which stimulates the Edinger-Westphal neurons and the ciliary ganglion neurons they innervate, thus constricting the pupil.

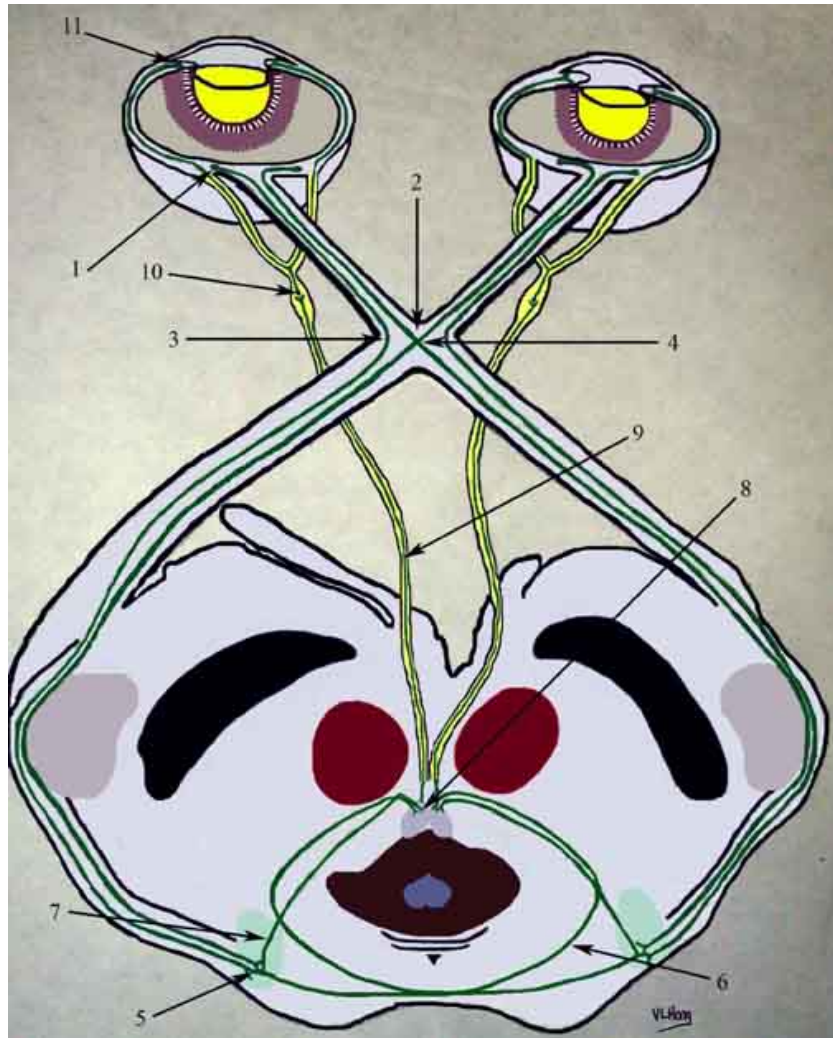


Fig. 39. This is another illustration to help you to understand the pupillary reflex pathway. The pupillary reflex can be thought of as an afferent limb, a parasympathetic efferent limb, and a sympathetic efferent limb. The afferent limb: light stimulates photoreceptors and the signal is conveyed to a special set of ganglion cells that send their nerve impulses thru the axons in a similar topographic distribution as those carrying other signals in the optic nerve (arrow 1). Decussation occurs at the optic chiasm (arrow 2) for the nasal fibers (arrow 4). The big difference is that the afferent fibers do not enter the lateral geniculate body but instead exit and pass thru the brachium of the superior colliculus (arrow 5) where they synapse on the pretectal olivary nuclei (arrow 7) (pontine olivary and sublentiform nuclei). These nuclei then project bilaterally to the Edinger-Westphal nuclei (arrows 6 and 7) via internuncial neurons by a process that has not been fully elucidated. The efferent parasympathetic response: The Edinger-Westphal nuclei send fibers to join the oculomotor nerve (CNIII) (arrow 8) and follow that course on the dorsomedial surface of the nerve (arrow 9). This point of anatomy is important, for this represents the outer surface of the nerve, which lies adjacent to the posterior

communicating artery and thus is exposed to the forces of herniation. After coursing through the cavernous sinus these fibers emerge to enter the orbit with the inferior oblique branch of CNIII. These fibers synapse at the ciliary ganglion (arrow 10) and then enter the eye through the short posterior ciliary nerves to distribute fibers to the choroid, iris (arrow 11), and the ciliary body. The red nucleus is shown in red and the substantia nigra in black. The medial geniculate body is dark gray and medial to the brachium of the superior colliculus. The lateral geniculate body where the fibers responsible for vision will synapse lie lateral to the pupillary fiber pathway. The efferent sympathetic response: this is believed to start in the hypothalamus and project in an uncrossed fashion with synapses in the midbrain and pons. These neurons project to and synapse upon the intermediolateral cell column from C8 to T2 in the spinal cord. These exit the spinal cord and pass through the stellate ganglion to synapse in the superior cervical ganglion. These fibers travel with the internal carotid artery, enter the cavernous sinus and travel with CNVI in the cavernous sinus to enter the superior orbital fissure with CNV. The fibers pass through the long ciliary nerves to terminate on the dilator muscle. Some fibers diverge in the superior orbital fissure to innervate Muller's muscle.

White Matter Tracts Connecting the Occipito-Temporal Lobes

Geniculocalcarine Tract

The magnocellular and parvocellular layers send their axons via the geniculocalcarine tract to the visual cortex completing the last visual relay. This tract extends from the LGN through the retrolenticular portion of the internal capsule and forms the optic radiations, which end in the striate cortex (Brodmann's area 17), located on the medial surface of the occipital lobe. These fibers terminate in both banks of the calcarine sulcus. All fibers of this radiation do not reach the cortex by the shortest route. The most dorsal fibers pass almost directly backward to the visual cortex. Those fibers, which are placed more ventrally first turn forward and downward into the temporal lobe, and spread out over the rostral part of the inferior horn of the lateral ventricle; these fibers then loop backward and run close to the outer wall of the lateral ventricle (Meyer's loop) to reach the visual cortex. The range of distance from the tip of Meyer's loop to the inferior horn (temporal horn) is 24 to 47 mm (mean 34 mm), with a trend toward the left Meyer's loop radiation extending more anteriorly than the right. The fibers forming Meyer's loop relay input from the inferior half of the retina and terminate in the inferior bank of the cortex lining the calcarine fissure. The more dorsal fibers represent input from the superior half

of the retina and terminate in the superior bank of the calcarine fissure. Thus, unilateral lesions in the temporal lobe affect vision in the superior quadrant of the contralateral visual hemifield of both eyes (contralateral quadrantic anopsia) because they disrupt Meyer' loop.

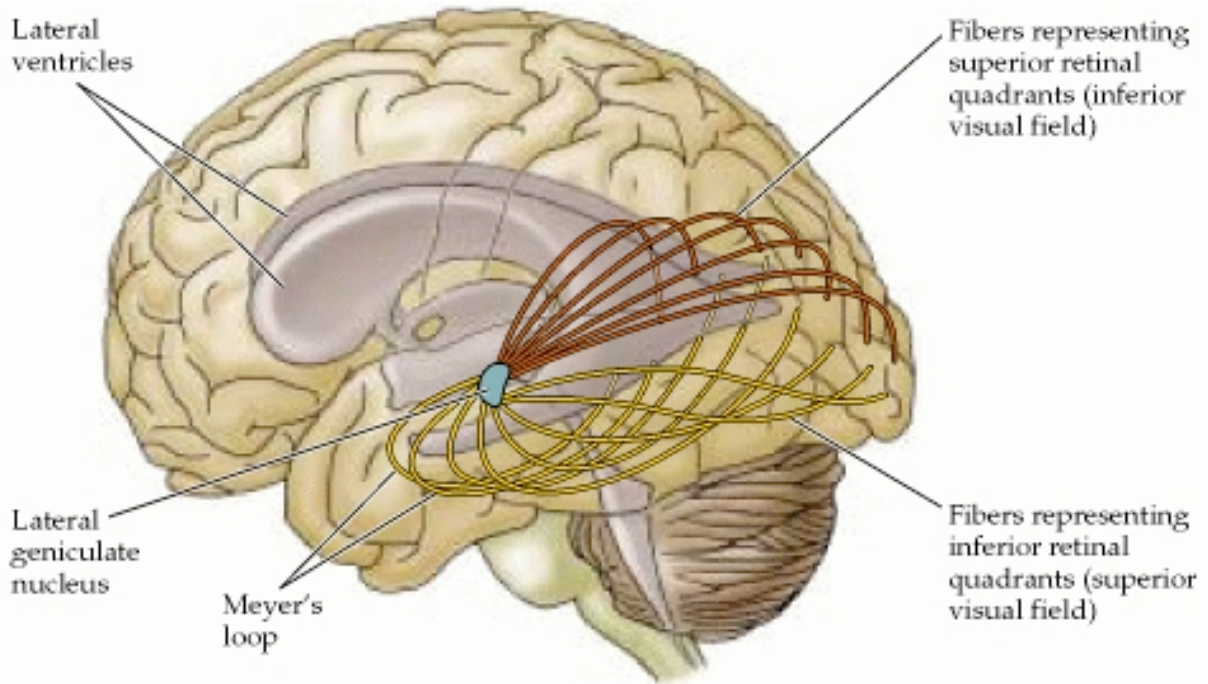


Fig. 40. This illustration depicts the course of the optic radiation to the striate cortex. Remember, fibers originating in the ipsilateral inferior temporal retina and the contralateral inferior nasal retina sweep anteriorly and laterally around the temporal horn (Meyer's loop) before transversing posteriorly to reach the occipital lobe. Meyer's loop carries information from the superior portion of the contralateral visual field. More medial parts of the optic radiation, which pass under the cortex of the parietal lobe, carry information from the inferior portion of the contralateral visual field. Damage to parts of the temporal lobe with involvement of Meyer's loop can thus result in a superior homonymous quadrantanopsia; damage to the optic radiation underlying the parietal cortex results in an inferior homonymous quadrantanopsia. Complete interruption of the optic radiations results in a contralateral total homonymous hemianopia.

Splenic Fibers

The splenic fibers arise from the corpus callosum and connect the medial cortex of the left and right occipital lobes. One region is located in the forceps major of the left cerebral hemisphere, and the other in the forceps major of the right hemisphere. The

splenic fibers provide a reference point from which to compare the anatomical relationships of the visual pathways and the **Inferior Longitudinal Fasciculus**.

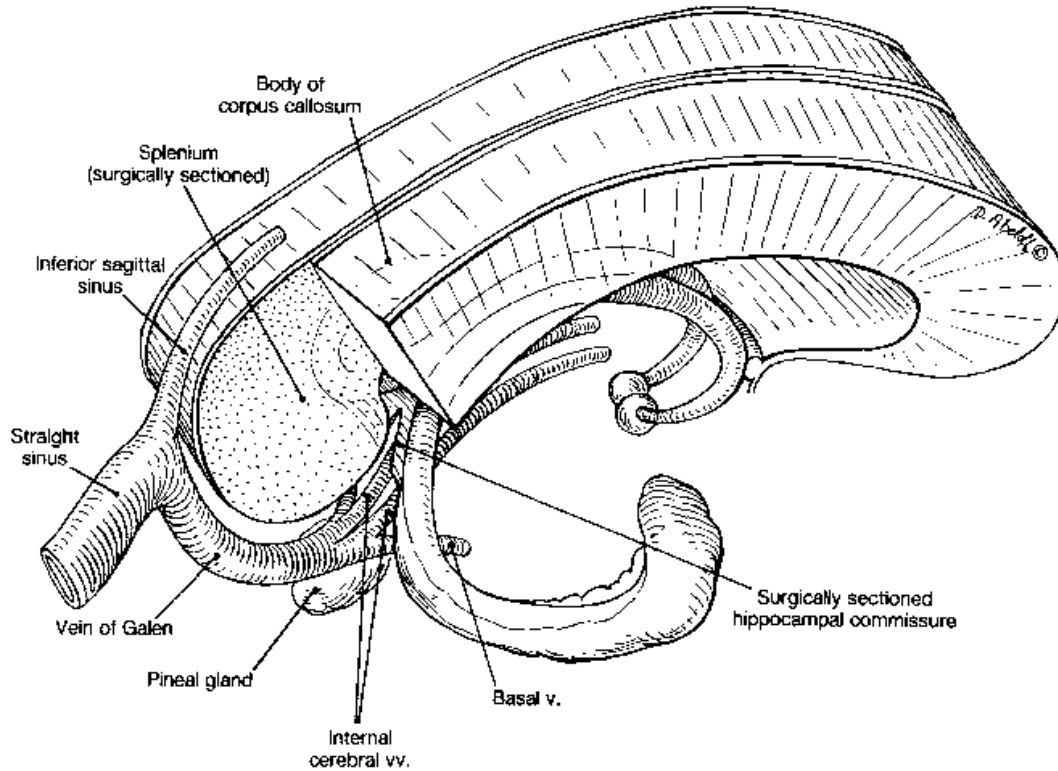


Fig. 41. This illustration shows the location of the splenium, which is in the most posterior aspect of the corpus callosum. Lesions in the splenium show effects of visuospatial cues. There may also be suppression of consonant-vowel syllables. This is believed to be evidence for the disruption of signals that normally alert the individual to the presence of behaviorally relevant stimuli, possibly originating in the temporoparietal junction area. After splenic lesions, these signals may not reach the contralateral hemisphere, leading to supramodal deficits in target detection, especially under distracting conditions.

Inferior Longitudinal Fasciculus (ILF)

This tract represents a white matter associative tract connecting the occipital and temporal lobes; described by a German neuroanatomist K. F. Burdach in 1822. Its existence however, was a matter of controversy for a period of time with some considering it a major occipito-temporal associative tract, whereas others denied its existence, suggesting that the connection between the occipital and temporal lobes is due

to the U-shaped association fibers (occipito-temporal projection system). In a paper written by Catani et al, entitled “Occipito-temporal connections in the human brain,” published in *Brain*, the existence of the ILF was substantiated. The results of their work indicated, that in addition to the indirect connections of the occipito-temporal projection system, there is a major associative connection between the posterior occipital lobe and anterior temporal lobe, with the cells of origin located in the extrastriate visual association areas, called the ILF. The fibers of the ILF are distinct from the U-shaped fibers connecting the adjacent gyri of the lateral occipito-temporal cortices to form the occipito-temporal projection system, which constitute an indirect connection between the occipital and temporal lobes; the fibers of the ILF are also distinct from the optic radiations, both dorsal and ventral (Meyer’ loop). The fibers of the ILF project from the extrastriate visual association areas to the lateral and medial anterior temporal regions. Initially the ILF arises from three branches: a lingual branch, a lateral occipital branch, and a cuneal branch. At the occipital horn of the lateral ventricle, the ILF fibers run laterally to the optic radiation and callosal (tapetal) fibers, the three bundles corresponding to the external, intermediate and internal sagittal strata of Sachs. At the level of the posterior horn of the lateral ventricle, they gather into a single bundle. In the anterior temporal lobe the fibers terminate in the lateral and medial temporal areas. The lateral temporal branches innervate the superior, middle and inferior temporal gyri and the medial branches innervate the parahippocampal gyrus.

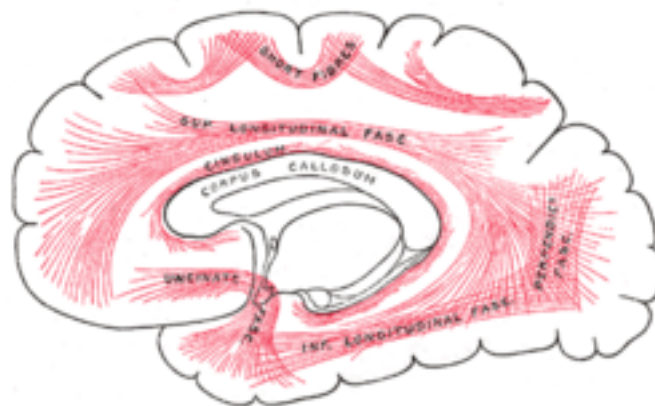


Fig. 42. In the above diagram the association fibers of the inferior longitudinal fasciculus are located inferiorly, running through the temporal lobe. As indicated in the written text, the IFL connects the temporal lobe and occipital lobe, running along the lateral walls of the inferior and posterior cornua of the lateral ventricle.

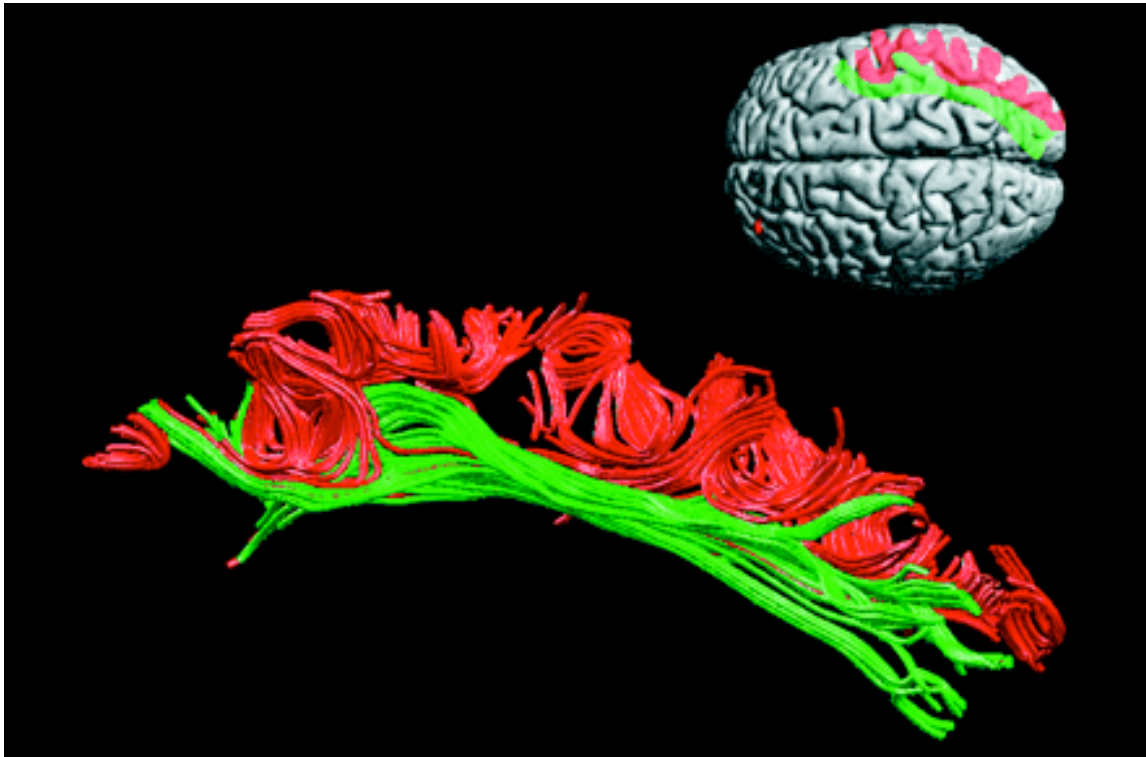


Fig. 43. The inferior longitudinal fasciculus (green) and the U-shaped fibers (red) of the right hemisphere. The U-shaped fibers are located laterally to the ILF and connects the adjacent gyri on the lateral occipito-temporal cortices to form the occipito-temporal projection system (temporal to the left of the lower diagram and occipital to the right). From 'Occipito-temporal connections in the human brain' by M. Catani et al. pp. 2093-2107.

Superior Longitudinal Fasciculus (SLF)

The SLF is a pair of long bi-directional bundles of neurons connecting the front and the back of the cerebrum. Each association fiber bundle is lateral to the centrum ovale of a cerebral hemisphere and connects the frontal, occipital, parietal, and temporal lobes. The neurons pass from the frontal lobe through the operculum to the posterior end of the lateral sulcus where numerous neurons radiate into the occipital lobe and other neurons

turn downward and forward around the putamen and radiate to the anterior portions of the temporal lobe. The SLF is composed of four distinct components: SLF I, SLF II, SLF III, and the arcuate fascicle (AF). In humans, these four components are bundled together although they are functionally separate.

SLF I connects the superior parietal cortex, which encodes locations of body parts in a body-centric coordinate system and with M II and the dorsal premotor cortex. This suggests the SLF I is involved with regulating motor behavior, especially conditional associative tasks, which select among competing motor tasks based on conditional rules. SLF II connects to the caudal inferior parietal cortex, which controls spatial attention and visual and oculomotor functions. This suggests the SLF II provides the prefrontal cortex with parietal cortex information regarding perception of visual space. Since these bundles are bi-directional, working memory (Brodmann 46) in the prefrontal cortex may provide the parietal cortex with information to focus spatial attention and regulate selection and retrieval of spatial information. SLF III connects the rostral inferior parietal cortex, which receives information from the ventral precentral gyrus. This suggests that the SLF III transfers somatosensory information, such as language articulation, between the ventral premotor cortex, Brodmann 44 (pars opercularis), the supramarginal gyrus (Brodmann 40), and the lateral inferior prefrontal cortex working memory (Brodmann 46). The AF connects the superior temporal gyrus with the dorsal prefrontal cortex, which suggests auditory information is transmitted between those two areas of the cortex.

U-shaped association fibers

These fibers are located lateral to the ILF and connect the adjacent gyri of the lateral occipito-temporal cortices to form the **occipito-temporal projection system (OTPS)**. These association fibers consist of short U-shaped fibers that course beneath the cortical mantle to connect adjacent regions in the striate and prestriate cortex and the inferior temporal cortex (see Fig. 43). This system serves as a functional interplay between the visual association cortex and the temporal lobe. The regions in the temporal lobe innervated by the OTPS subsequently project to the limbic system. The OTPS has been implicated in **prosopagnosia**, which is often referred to as visual-limbic disconnection

syndrome. Individuals with prosopagnosia suffer from a decrease in emotional responsiveness to visual stimuli.

Visual Cortex (Brodmann's areas 17, 18 and 19)

The visual cortex refers to the **primary visual cortex**, also known as the **striate cortex** or **V1** and the **extrastriate visual cortical areas V2, V3, V4, MT (V5), V6 (PO), V7, and V8**. The **primary visual area is Brodmann's area 17 (V1)**, which is located in the walls of the calcarine sulcus and adjacent portion of the cuneus and lingual gyrus, receives visual input from the LGN. The cortex in this region of the occipital lobe is exceedingly thin measuring between 1.5 and 2.5 mm. It consists of 6 layers of cells, numbered 1 through 6. Layers 2 and 3 are narrow and contain numerous small pyramidal cells that are hardly larger than typical granule cells; layer 4 is very thick being subdivided by a light band composed of myelinated fibers into sublayers 4A, 4B, 4C α , and 4C β . This light band is visible to the naked eye and is referred to as the **band of Gennari (stria of Gennari)**, hence the name **striate cortex**.

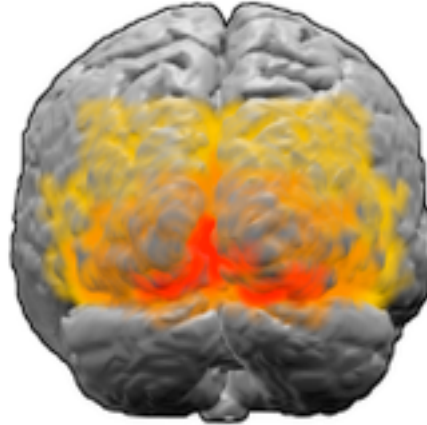


Fig. 44. This illustration shows the brain from behind. Red represents Brodmann area 17 (primary visual cortex); orange represents area 18 and yellow area 19.

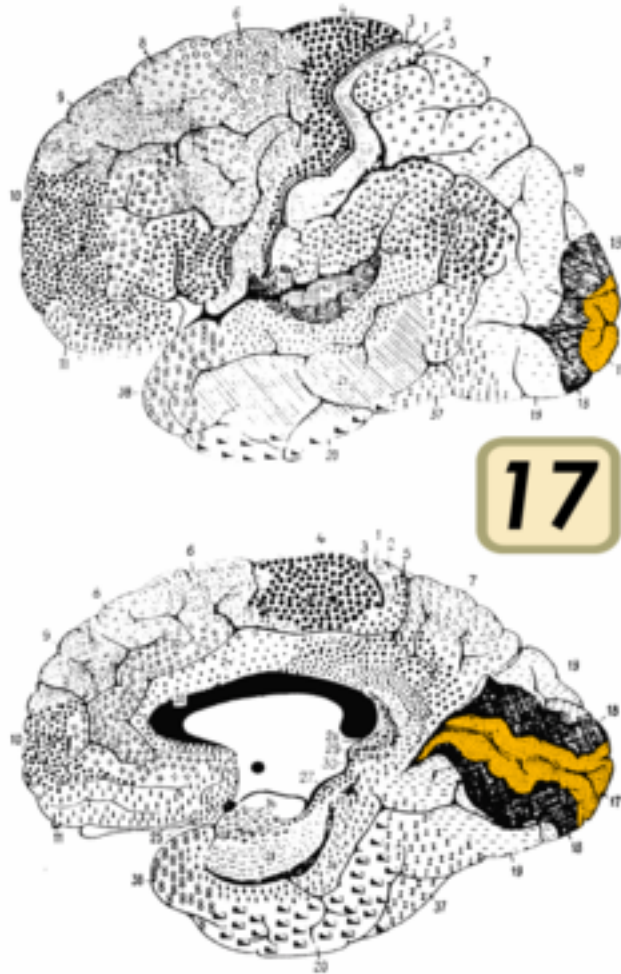

Fig. 45. This is an illustration showing the left cerebral hemisphere of the brain from its lateral (upper) and medial (lower) sides. The lower image is produced by cutting the brain down the middle, separating the left and right cerebral hemispheres. Brodmann area 17 is in orange. The intensely black area adjacent to area 17 is primarily V2 of the extrastriate cortex.

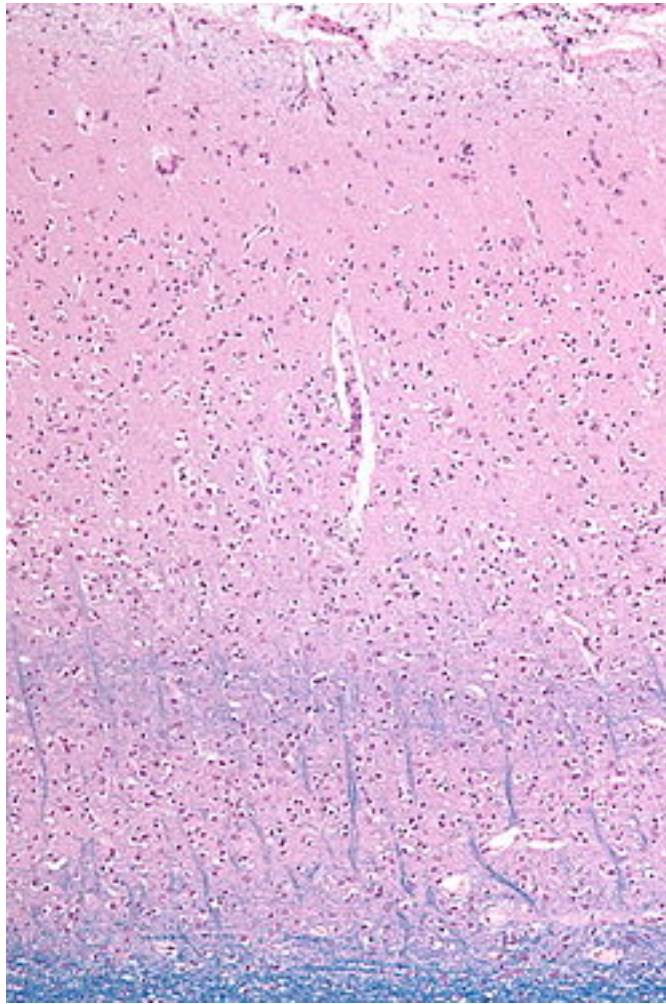


Fig. 46. The above photomicrograph is of the visual cortex, which is represented by the pink color. Toward the lower half of this image is a faint blue band, which is called the line of Gennari (Band of Baillarger). The subcortical white matter (darker blue) is seen at the very bottom of the image. The line of Gennari represents a band of myelinated axons projecting into layer 4β of the primary visual cortex from layer $4C\alpha$. This formation, as can be seen in this image, is visible to the naked eye, and is coterminous with area V1.

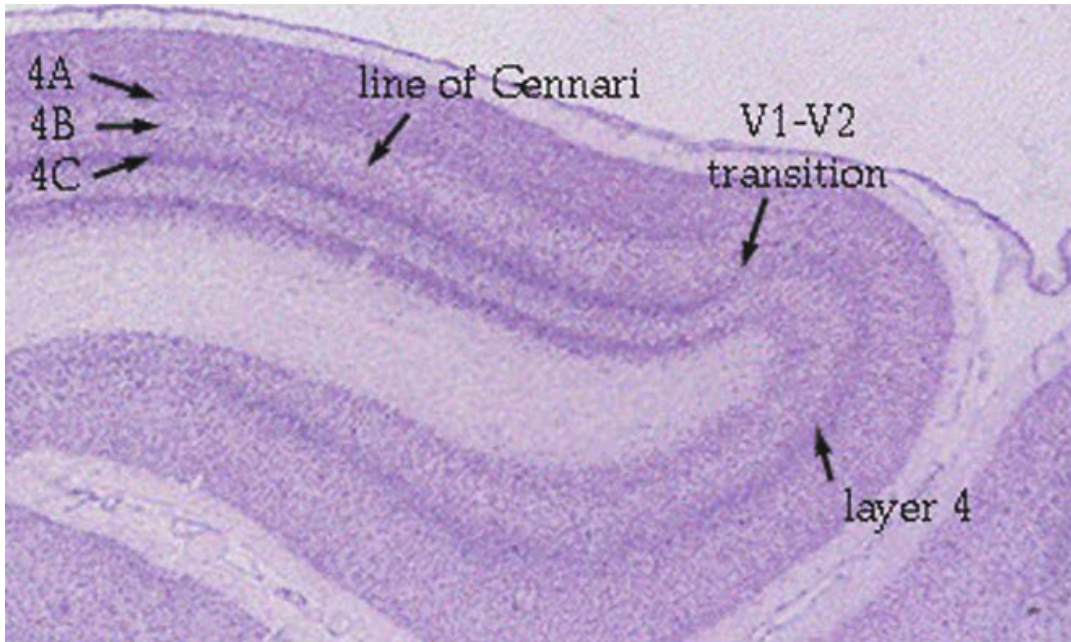


Figure 9. Nissl stained section of the visual cortex to show the border between area 17 (V1) and area 18 (V2).

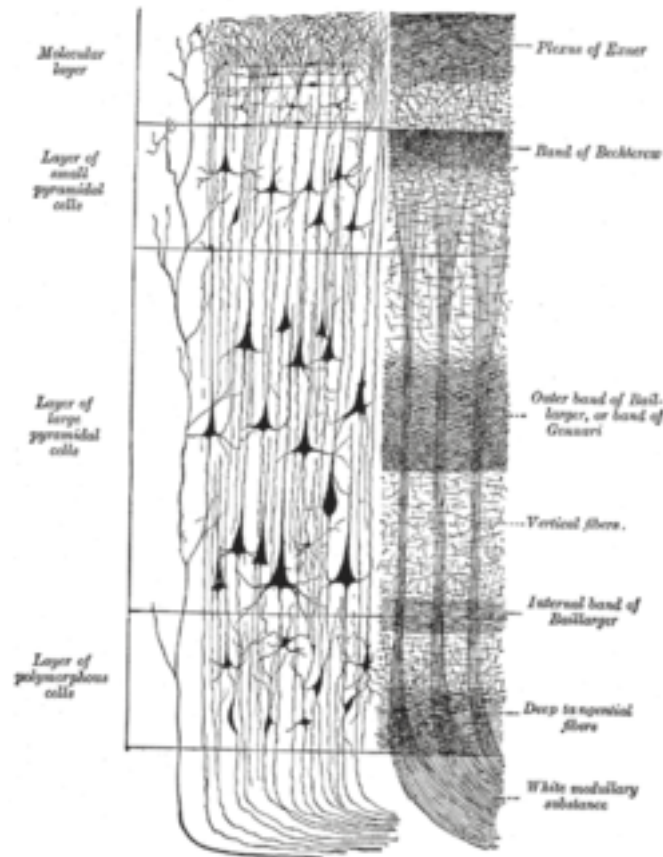


Fig. 47. The above is a drawing of the primary visual cortex showing the cellular makeup of the line of Gennari. To the left is the group of cells in each layer and to the right, the system of fibers. To the left of the group of cells is a sensory fiber.

The axons of the M cells of the LGN terminate primarily in $4C\alpha$; the axons of most P cells terminate principally in $4C\beta$. The axons from the koniocellular cells terminate in layers 2 and 3, where they innervate patches of cells called blobs, which constitute a functional unit of cells. The organization of the visual cortex into functional modules will be discussed at the end of this section. As previously indicated the k cells form what is referred to as the k pathway, which is believed to be a pathway in parallel to the P and M pathways from the retina to the visual cortex, and is primarily concerned with determination of color.

The optic radiations (geniculocalcarine fibers) projects topographically upon the striate cortex so that cells in: (1) the medial half of the LGN, representing upper retinal quadrants (lower quadrants of the visual field) project to the superior bank of the calcarine sulcus, and (2) the lateral half of the LGN (upper quadrants of the visual field) project to the inferior bank of the calcarine sulcus. The macular fibers terminate in the caudal third of the calcarine area, and those from the paracentral and peripheral retinal areas end in respectively more rostral portions. The representation of the macular area in the occipital cortex appears relatively large compared with the macular area of the LGN. What is important to remember is that approximately 50% of the entire neural mass in both banks is devoted to representation of the macula; this is due to the fact that this area of the retina has the greatest visual acuity. The primary visual cortex (V1) serves as a well-defined map of spatial information, which in actuality represents a transformation of the visual image from the retina to V1. V1 utilizes two pathways to project information, the dorsal pathway and the ventral pathway.

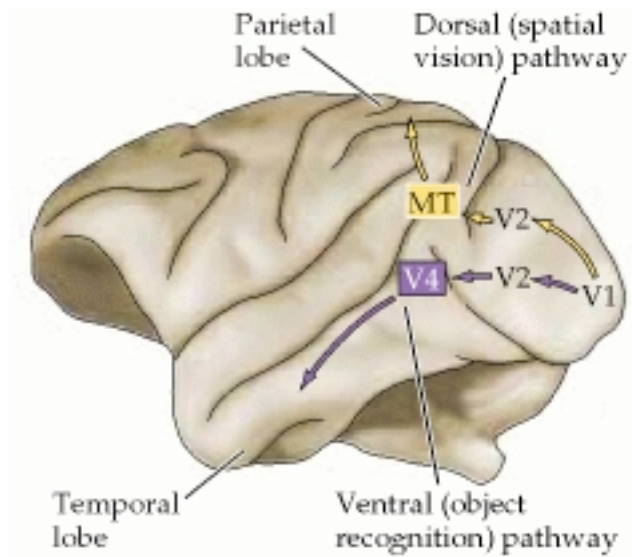


Fig. 48. This is a diagram representing the visual areas beyond the striate cortex, which is broadly organized into two pathways: a ventral pathway that leads to the temporal lobe, and a dorsal pathway that leads to the parietal lobe. As previously indicated, the ventral pathway plays an important role in object recognition, the dorsal pathway in spatial vision.

The dorsal pathway sends information first to V2 and then to the dorsomedial area and V5 and to the posterior parietal cortex. It is associated with motion, representation of object locations, and control of the eyes and arms, especially when visual information is used for reaching and saccades, which will be described below; the dorsal pathway is sometimes referred to as the “where” system. It includes V1, V2, V3, V3A, V4, MT (medial temporal area, V5), V6/V6A (PO, occupies the posterior face of the superior parietal gyrus; V6 occupies the upper portions of the bank and V6A occupies the lower portions of the bank), V7, MST (medial superior temporal area), and STP (superior temporal polymodal area, i.e., a polysensory area situated in the dorsal bank of the superior temporal sulcus, and the parietal eye field, Brodmann’s area 7). All of these areas, with the exception of V1 are part of the extrastriate visual cortex (visual association cortex), which will be discussed below.

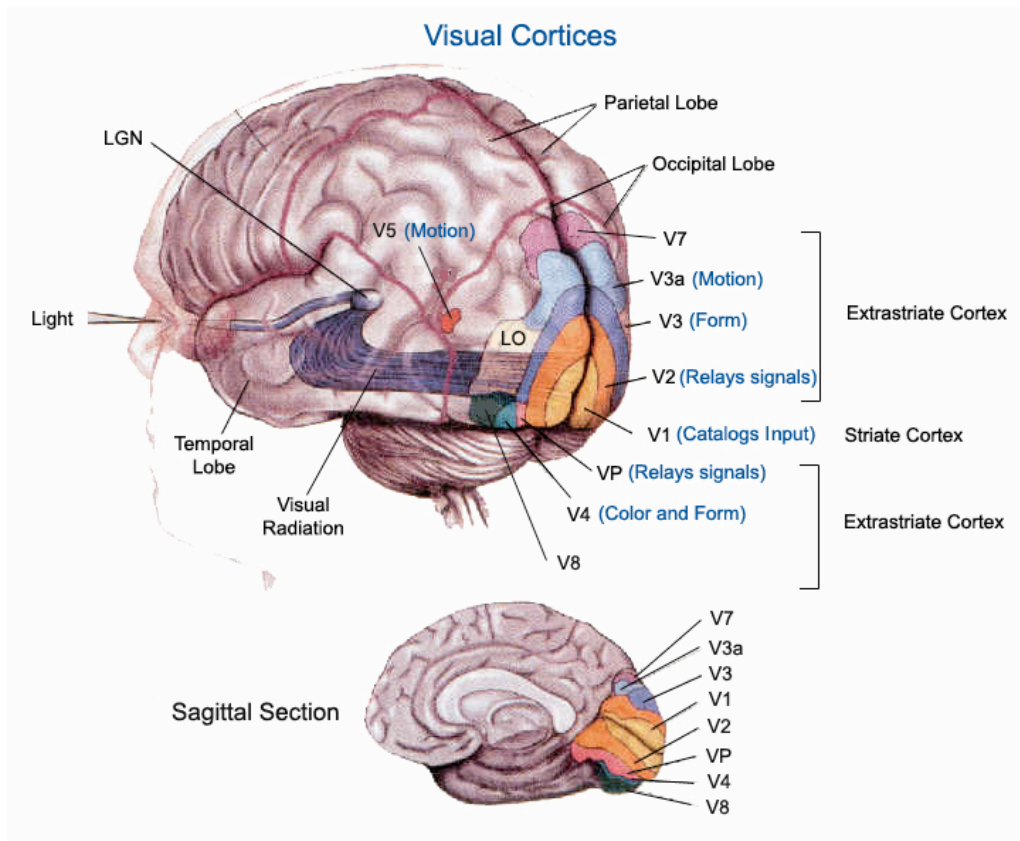


Fig. 49. This is a drawing of the visual cortex in which projections that come from our eyes first go through an intermediate structure in the middle of the brain called the LGN. From the LGN the visual images are passed on to the visual cortex. The visual cortex is mainly divided into five areas: V1, V2, V3, V4, and MT, which is also known as V5. In a very general sense, the neurons in the visual cortex are organized in a special way to detect different colors, motion, size and many other things.

STP responds to visual, auditory and somatosensory stimuli. It interacts with the inferior temporal cortex. The parietal eye field refers to the area surrounding the parietal sulcus, which contains at least 5 subdivisions, all of which are concerned with highly specialized visual functions. It functions as a visual-motor interface. It is reciprocally connected with V1, V2 and V3 through direct and indirect pathways passing through MT, MST and V3A.

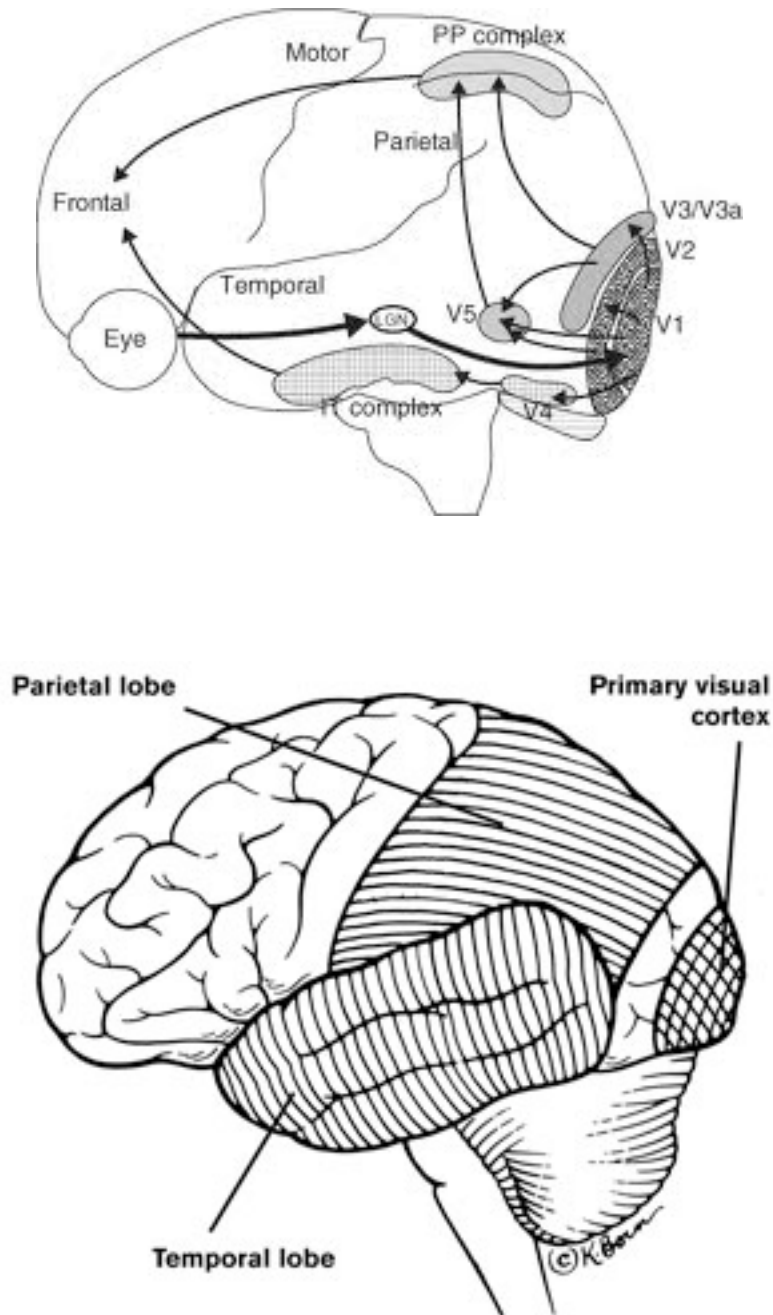


Fig. 50. The above diagrams are an effort to reinforce the concept that visualization requires more than seeing. The primary visual cortex recognizes and processes information from our eyes, but areas of the temporal lobe are necessary for recognizing what we see: objects, faces, and so on. Areas of the parietal lobe process information about moving through the space we see.

Although not technically considered a part of the dorsal pathway, the frontal lobe contains three fields which give rise to eye movements when stimulated, namely the frontal eye field, situated in the most posterior part of the middle frontal gyrus, the prefrontal eye field, located more anteriorly in Brodmann's area 46, and the supplementary eye field, situated dorsally, in the most rostral part of Brodmann's area 6. All three of these frontal eye fields are heavily and reciprocally connected with the parietal eye field.

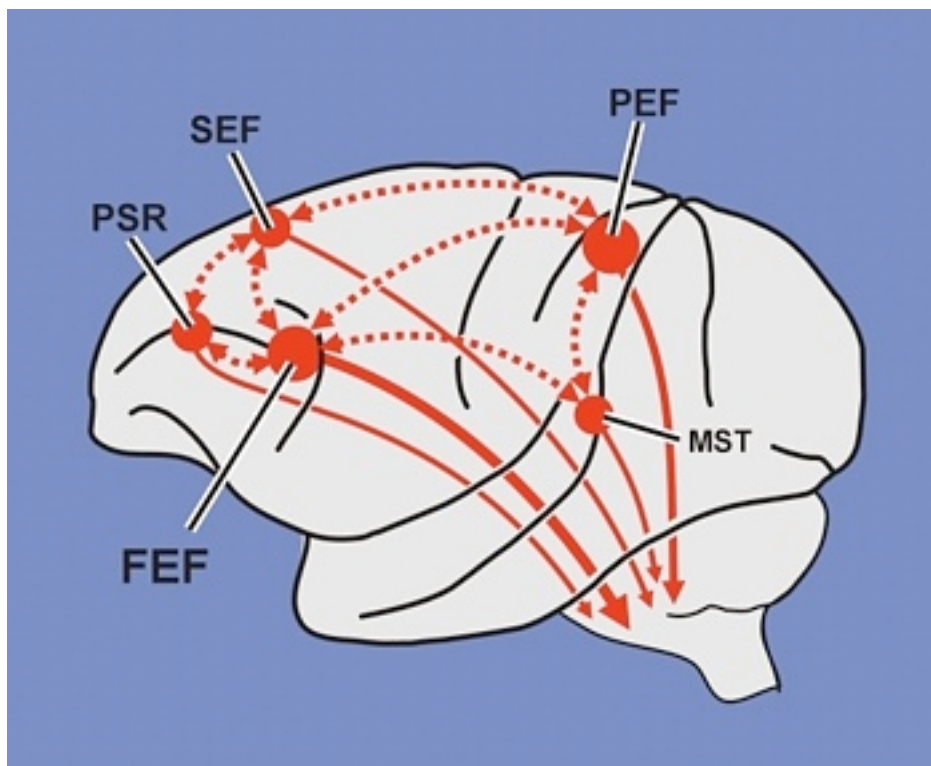
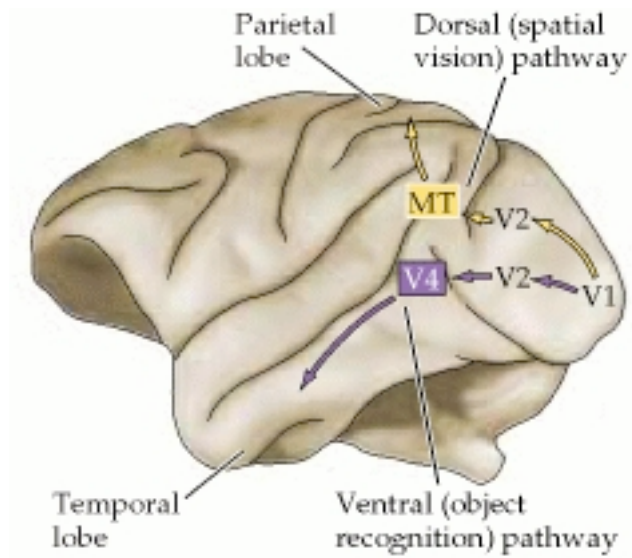


Fig. 51. This illustrations represent the cortical eye fields in the monkey. Most eye fields contain discrete subregions that participate in the control of either saccadic or smooth pursuit eye movements. Each eye field has direct projections to the brainstem oculomotor system, and each eye field is connected reciprocally with most other eye fields. FEF, frontal eye field; MST, medial superior temporal area; PEF, parietal eye field; PFEF, prefrontal eye field; SEF, supplementary eye field. Adapted from Lynch, J. C and Tian, J. R. Cortico cortical networks and cortico subcortical loops for the higher control of eye movements. *Progress in Brain Research* 151: 461 501, 2006.

A saccade, as previously indicated, is a fast movement of an eye, head or other part of ones body. When used in reference to movement of an eye, it refers to quick,

simultaneous movements of both eyes in the same direction. By utilizing a saccade the central part of the retina, the fovea, plays a critical role in resolving objects. By moving the eye so that small parts of a scene can be sensed with greater resolution, we can utilize our body movements far more efficiently.

The way in which we are able to perceive motion is through the magnocellular pathways to middle temporal (MT) areas and the medial superior temporal (MST) areas as well as the visual motor area of the parietal lobe (the dorsal pathway). The neurons within the MT area respond to velocity and movement direction of objects. These neurons in turn project to neurons within the MST area which further process this information with the net effect being visual perception is defined and how the eye movements will pursue the perceived object along with how our entire body will be guided toward the perceived object.



The ventral pathway sends information to V2, then through V4, and to the inferior temporal cortex. The ventral pathway is associated with form recognition and object representation; it is often referred to as the “what” system. Areas V1, V2, LO (lateral occipital area), V4/V8 and the entire inferotemporal cortex, composed of Brodmann’s areas 37, 20 and 21, are included in the ventral pathway. V8 is sometimes labeled as

VO-1 (ventral-occipital cortex). All of these areas, with the exception of V1, are considered part of the extrastriate visual cortex, which will be discussed below. Most of the fibers, interconnecting the various areas participating in this stream, pass forwardly in the inferior longitudinal fasciculus. It has been demonstrated in the posterior part of the inferotemporal cortex there is reciprocal connections with the parietal and frontal eye fields; hence the dorsal and ventral pathways are not rigidly separate. The ventral pathway is also associated with long-term memory.

There is clinical evidence, which supports the existence of these parallel process pathways (dorsal & ventral pathways). There is a perceptual deficit called “movement agnosia,” which occurs with damage to the MT or MST regions of the cortex, which are part of the dorsal pathway. These patients show a specific loss of motion perception without any other perceptual problems. Patients who have damage to the ventral pathway, lose color vision (achromatopsia) and the ability to identify forms.

The inferior temporal lobe includes separate subregions sensitive to different object characteristics. Experiments recording neurons in the monkey have shown that cells in the visual cortex area V2 (Brodmann’s area 18) analyze object contours (shape discrimination). Cells in V4 respond to color and form. Neurons in the inferior temporal cortex have large receptive fields, meaning they recognize the same features anywhere in the visual field, thus allowing us to recognize the same object wherever it is situated in space. There are also neurons within the inferior temporal cortex, which respond only to complex inputs, such as faces or hands.

Monkeys with lesions in the inferotemporal cortex are very impaired in visual pattern discrimination and recognition, but less impaired in solving tasks involving spatial cues. The opposite pattern is seen in monkeys with posterior parietal lesions.

The **extrastriate visual cortical areas (or visual association cortex)** are represented by V2, V3, V3A, V4, DP (the dorsal prelunate gyrus), V5 (MT), MST, STP, VP, LO, V6/V6A, V7, and V8. The extrastriate visual cortical areas are characterized by the fact their principal afferents arise either directly or indirectly from the striate area, hence their name. The extrastriate visual cortical areas involve Brodmann’s areas 7, 18-21, 37, and

39. It appears that when you consider all of Brodmann's areas involved in visual processing they occupy approximately 1/3 of the neocortex. V2 is referred to as the prestriate cortex (Brodmann's area 18), which also includes V3, and occupies the bulk of the occipital lobe. It is the second major area in the visual cortex, and the first region within the visual association area. Anatomically it includes parts of the cuneus, the lingual gyrus and the lateral occipital gyrus. It forms a border with area 17 from which it can be distinguished by the lack of the band of Genari, which as previously indicated, is the prominent stripe of white matter in layer 4 of area 17. V2 receives and sends projections to V1 and sends projections to V3, V4 and V5. V2 is divided into 4 quadrants, a dorsal and ventral in both the left and right hemispheres. Together these four quadrants provide a complete visual image. V2 is involved in orientation, spatial frequency and color vision. V2 also is involved to a small degree in attentional modulation (more than V1, less than V4), and are tuned for moderately complex patterns. Brodmann's area 19 includes V3, VP (ventroposterior visual area and is anterior to the basal part of V2. Some have argued this area in reality represents the ventral part of V3), V3A, V4v, V8 and V5/MT. V3 refers to that area immediately in front of V2, which along with V2 forms the prestriate cortex. Brodmann's area 19, is composed by parts of the lingual gyrus, the cuneus, the lateral occipital gyrus and the superior occipital gyrus of the occipital lobe. Rostrally it forms a boarder with Brodmann's area 39 (angular area/ angular gyrus), Brodmann's area 37 (occipitotemporal area) and the parietooccipital fissure; caudally and posteriolaterally it surrounds Brodmann's area 18. Some refer to V3 as the third visual complex. This line of thought is based on the belief that V3 consist of at least two subdivisions, dorsal V3 and ventral V3. Dorsal V3 is further subdivided into V3A and V3B. V3A occupies the most superior part of the occipital lobe, extending over both the lateral and medial surface of the hemisphere. V3A contains a central field representation that is distinct from the foveal representation at the confluence of areas V1, V2 and V3. Adjacent to V3A is a second visual area, V3B, which represents both the upper and lower quadrants. The central representation in V3B appears to merge with that of V3A. Dorsal V3 receives projections from V2 and V1 and sends projections to the

posterior parietal cortex. Dorsal V3 may play a role in global motion. Some believe dorsal V3 is part of a larger area called the dorsomedial area, which contains a representation of the entire visual field. Ventral V3 has some inputs from V1 and sends projections to the inferior temporal cortex. It is referred to as the ventrolateral posterior area (VLP). Recent research as shown it contains a complete representation of the visual field.

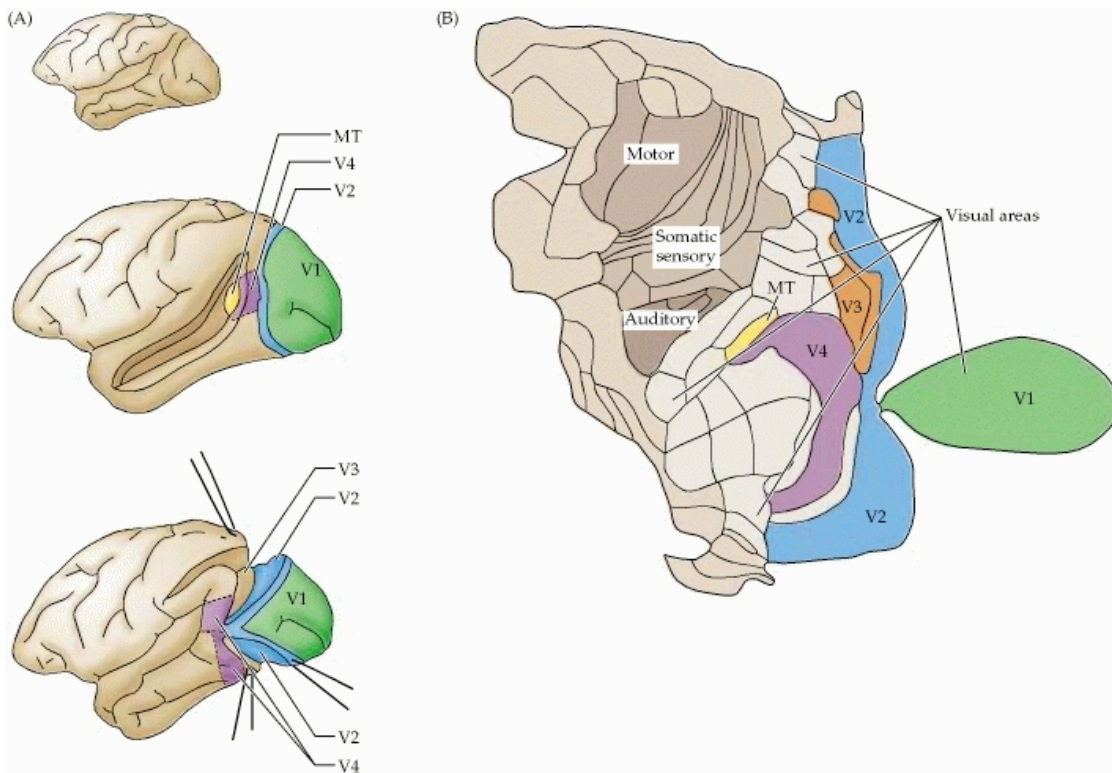


Fig. 52. The above diagrams represent the subdivisions of the extrastriate cortex in the macaque monkey. (A) Each of the subdivisions indicated in color contains neurons that respond to visual stimulation. Many are buried in the sulci, and the overlying cortex must be removed to expose them. Some of the more extensively studied extrastriate areas are specifically identified (V2, V3, V4, and MT). V1 is the primary visual cortex; MT is the middle temporal area. (B) The arrangement of extrastriate and other areas of the neocortex in a flattened view. There are at least 25 areas that are predominantly or exclusively visual in function, plus 7 other areas suspected to play a role in visual processing. (A after Maunsell and Newsome, 1987; B after Felleman and Van Essen, 1991.)

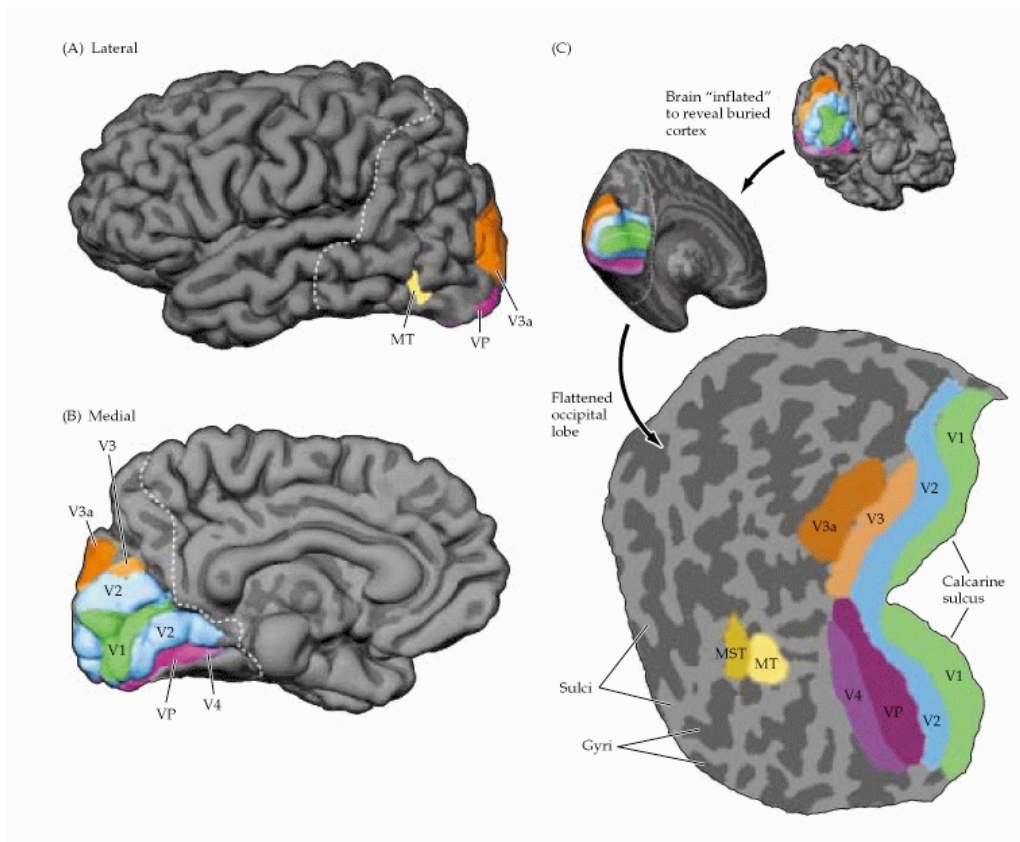


Fig. 53. These illustrations show the localization of multiple visual areas in the human brain using MRI. (A,B) Lateral and medial views (respectively) of the human brain, illustrating the location of primary visual cortex (V1) and additional visual areas V2, V3, VP (ventral posterior area), V4, MT (middle temporal area), and MST (medial superior temporal area). (C) Unfolded and flattened view of retinotopically defined visual areas in the occipital lobe. Dark grey areas correspond to cortical regions that were embedded in sulci; light regions correspond to regions that were located on the surface of the gyri. (After Sereno et al., 1995.)

There is another dorsal representation of the central visual field, which is referred to as area V7, which includes a representation of both the upper and lower quadrants of the visual field. It does appear that the receptive field properties of the neurons in V7 are different from those in V3A and V3B.

V3A, V7 and adjoining areas in the parietal lobe form a complex that is activated by saccades, which have been previously described, and attention.

Visual area V4 has been identified in the region of the occipital lobe comprised by Brodmann's areas 18 and 19, which is also referred to as the extrastriate visual cortex in

the macaque monkey. It consists of at least four regions (left and right V4d, left and right V4v). It receives strong input from V2 and sends projections to the posterior inferotemporal cortex (PIT). It also receives inputs from V1. In addition, it has weaker connections to V5 and visual area DP (the dorsal prelunate gyrus). V4 shows strong attentional modulation. Like V1, V4 is tuned for orientation, spatial frequency, and color. Unlike V1, it is tuned for object features of intermediate complexity, like simple geometric shapes. V4, however, is not tuned for complex objects such as faces, as some of the areas in the inferotemporal cortex are. The human homologue of V4 has not been clearly defined.

Visual area V5, also referred to as visual area MT (middle temporal), is that region of Brodmann's areas 18 & 19, that is believed to play a role in the perception of motion, the integration of focal motion signals into more generalized perceptions and the guidance of some eye movements. V5 receives inputs from layer 4 β in V1 as well as V2, dorsal V3 and the koniocellular regions of the LGN and the inferior pulvinar. V5 sends projections to the fundus of the superior temporal sulcus (FST), medial superior temporal area (MST) and V4 τ (middle temporal crescent). It appears that visual area V5 is involved in the processing of visual motion. Bilateral lesions that include this area cause a severe impairment in detecting the movements of objects, known as cortical akinetopsia.

The cells in V6 are more strongly connected with the lower visual areas (V2, V3, V3A, V5 and MST). The cells in V6A get no input from V2, weak input from V3 and V3A, and "ascending" input from V5. V6 and V6A are strongly interconnected, and the laminar distribution of terminals suggests that V6A is above V6 in the hierarchy. Both V6 and V6A project to Brodmann's area 6, which is premotor cortex.

Area V8, is sometimes labeled V4, borders laterally to LO (plays a role in recognizing large scale objects) and extends basally over the posterior parts of the lateral and medial occipitotemporal gyri. In actuality, LO is a complex, which includes LOC and LOP) and overlaps with what some call V3B and KO. This area is involved in color perception. Lesions in this region cause central color blindness (achromatopsi).

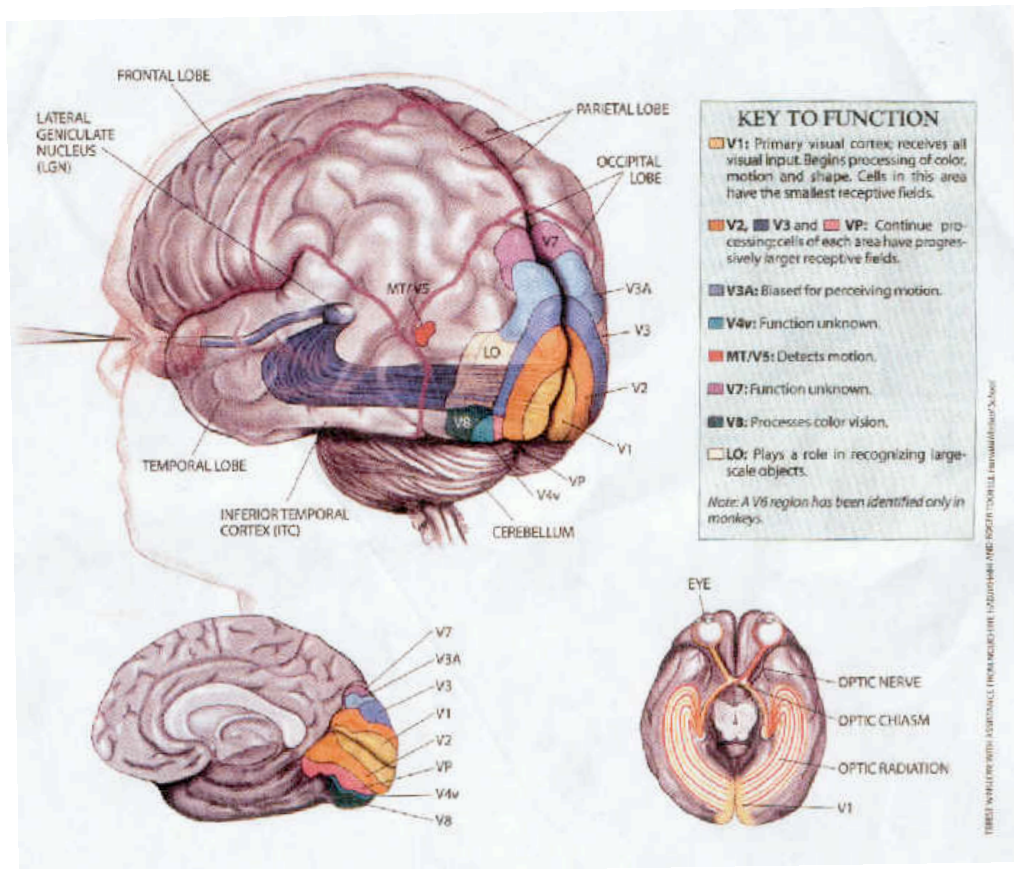


Fig. 54. The above represents the visual cortex in humans

The fusiform face area (FFA) is located in the fusiform (or lateral occipitotemporal) gyrus, which is part of the temporal lobe and is represented by Brodmann's area 37. It is directly in front of V8. This area is selectively responsive to faces and body recognition, word recognition, number recognition, processing of color information and abstraction. Lesions in the FFA can lead to prosopagnosia, a selective difficulty identifying faces. Recent research has demonstrated activation of the fusiform gyrus during subjective grapheme color perception in people with synesthesia. Synesthesia is an unusual conscious experience, in which stimulation of one sensory modality leads to a sensory experience in a second, unstimulated sensory modality. For example, seeing letters might lead some people to see colors. Others report that the days of the week or months of the year are arranged like a map in space. Still others report

that hearing voices or music cause them to see colors, or that hearing words makes them taste foods....in fact, almost any sensory modality can be involved in synesthesia.

The “binding problem”

How do we take the information processed by these pathways and organize it into a perceptual whole? This process by which the brain recombines information processed in its different regions is called the “binding problem.” The recombination of this information requires attention, which may be mediated by subcortical structures such as the superior colliculus, as well as cortical areas, such as the posterior parietal and prefrontal cortex. It has been hypothesized that the CNS takes information related to color, size, distance, and orientation and organizes it into a “master map” of image. Our attentional system allows us to focus on one small part of the “master map” as we identify objects or move through space.

It is further hypothesized that information from neural events in many different parts of the cortex (visual, auditory, kinesthetic, memory, etc.) are integrated by the cortex to produce perceptual binding through synchronizing their neural activation patterns, leaving all other neural activations non-synchronized. According to this hypothesis, multiple inputs compete for access to an attentional network; those that, “win”, become part of our conscious experience. According to this hypothesis, the brain is divided into two separate computational areas: network processors and a global neuronal workspace. In this hypothesis there are innumerable subcortical networks in the brain, and also much of the cerebral cortex, that can be considered to be like modular processing networks for particular types of information (e.g., motion processors or visual word-form processors). In addition to these processing networks there is a special set of cerebral cortex neurons, the global workspace neurons, which have long-range axons and can send and receive information from modular processors in distant parts of the brain. The unconscious information from modular processors would be temporarily made available (and therefore conscious) to the global workspace when those processors begin to fire in synchrony with their global neurons. This happens when the signals from the modular processors either become strong enough to “catch the attention” of the global neurons (a bright flash of

light or a loud noise), or the material they are conveying matches the “interest patterns” that the global workspace deems significant (you shift your focus to something, so the sensory input connected with it suddenly becomes relevant to the processing mechanism of the global workspace). At any moment in time, there would be a single global representation of workspace neurons and modular processors that are firing in synchrony and thus part of conscious awareness, with the rest of the workspace neurons (neurons in other processing modules) being inhibited.

Organization of the Visual Cortex into Functional Modules

The research of Hubel and Wiesel has shown the primary visual cortex of monkeys is organized into three different functional modules, which are arranged in column-like structures: **orientation columns, blobs and ocular dominant columns**. These columns in turn are united into larger structures referred to as **hypercolumns**.

The **orientation columns** consist of narrow columns of cortical cells, running from the pial surface to the white matter. Each column is about 30 to 100 μm wide and 2 mm deep, and each contains cells in layer 4C with concentric receptive fields. Above and below are simple cells whose receptive fields monitor almost identical retinal positions and have identical axes of orientation (i.e. cells that respond strongest to a bar of light which is in one particular orientation). For this reason these groupings are called orientation columns. Each orientation column also contains complex cells. The properties of these complex cells can most easily be explained by postulating that each complex cell receives direct connections from the simple cells in the column. Thus, columns in the visual system seem to be organized to allow local interconnection of cells, from which the cells are able to generate a new level of abstraction of visual information. For instance, the columns allow cortical cells to generate linear receptive field properties from the inputs of several cells in the lateral geniculate nucleus that respond best to small spots of light. Hubel and Wiesel went on to show there was a precise organization in the shift in axis of cellular organization of one orientation column to the next orientation column's axis of cellular organization. Within the primary visual cortex there appears to be a complete cycle of orientation change every three-quarters of a millimeter; these

systematic shifts from one axis of orientation of one column to the next is occasionally interrupted by structures called “blobs.”

Figure 10.26
A cortical module.

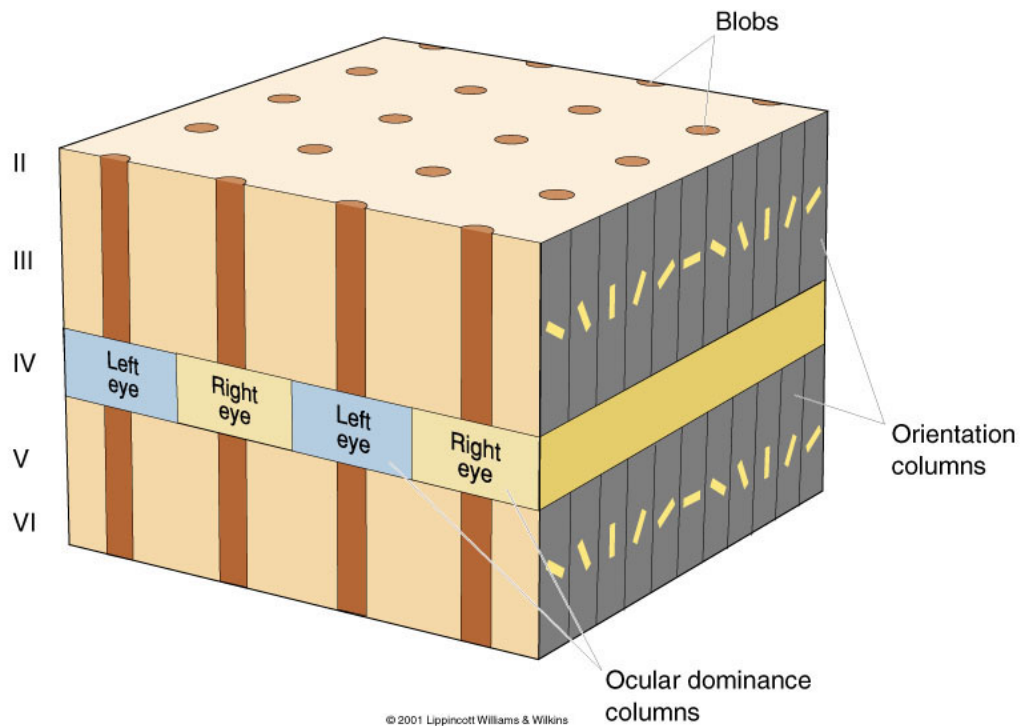


Fig. 55. This is a 1 mm by 1 mm region of the visual cortex illustrating cortical architecture, which occasionally is referred to as the “Ice Cube” model of the visual cortex, which contains all orientations, columns for both the left and right eyes, and blobs. It contains all of the processing machinery for one small region of visual space. This “Ice Cube” is repeated over and over again across the visual cortex, and is a prime example of the columnar organization of the cortex.

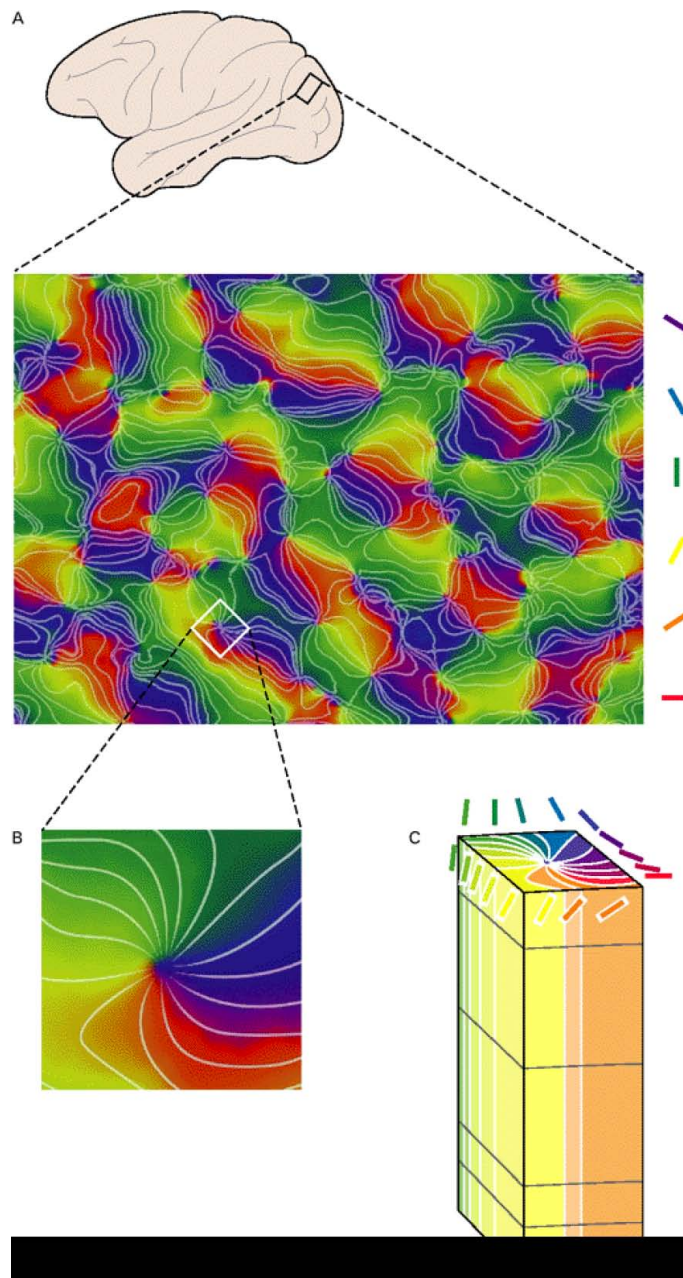


Fig. 56. This illustration depicts the orientation columns in the visual cortex of the monkey.

A. Represents the image of a 9 by 12 mm rectangle of the cortical surface taken while the monkey viewed contours of different orientations (indicated on the right). This image was obtained through optical imaging and by comparing local changes in reflectance, which indicate activity. Areas that were most active during the presentation of a particular orientation are indicated by the color chosen to represent that orientation (bars on the right). Complementary colors were chosen to represent orthogonal orientations. Hence, red and green indicate maximal activities in response

to horizontal and vertical, while blue and yellow indicate greatest activation by left and right oblique.

- B. This image represents an enlargement of a pinwheel-like area in A. Orientations producing the greatest activity remain constant along radials, extending outward from a center, but change continuously (through $\pm 18^\circ$). C. Three-dimensional organization of orientation columns in a 1 mm x 1 mm x 2 mm slab of primary visual cortex underlying the square surface region depicted in B. (Courtesy of Gary Blasdel)

“**Blobs**” are peg-shaped regions of cells located in layers 2 and 3 of V1. The cells forming these “blobs” are arranged in a peg-like (ellipsoid) arrangement measuring approximately 150 x 2000 μm . Their most superficial parts receive separate projections from the intercalated layers of the LGN. The cells forming the blobs respond to different color stimuli, and their receptive fields, like those of cells in the lateral geniculate nucleus, have no specific orientation.

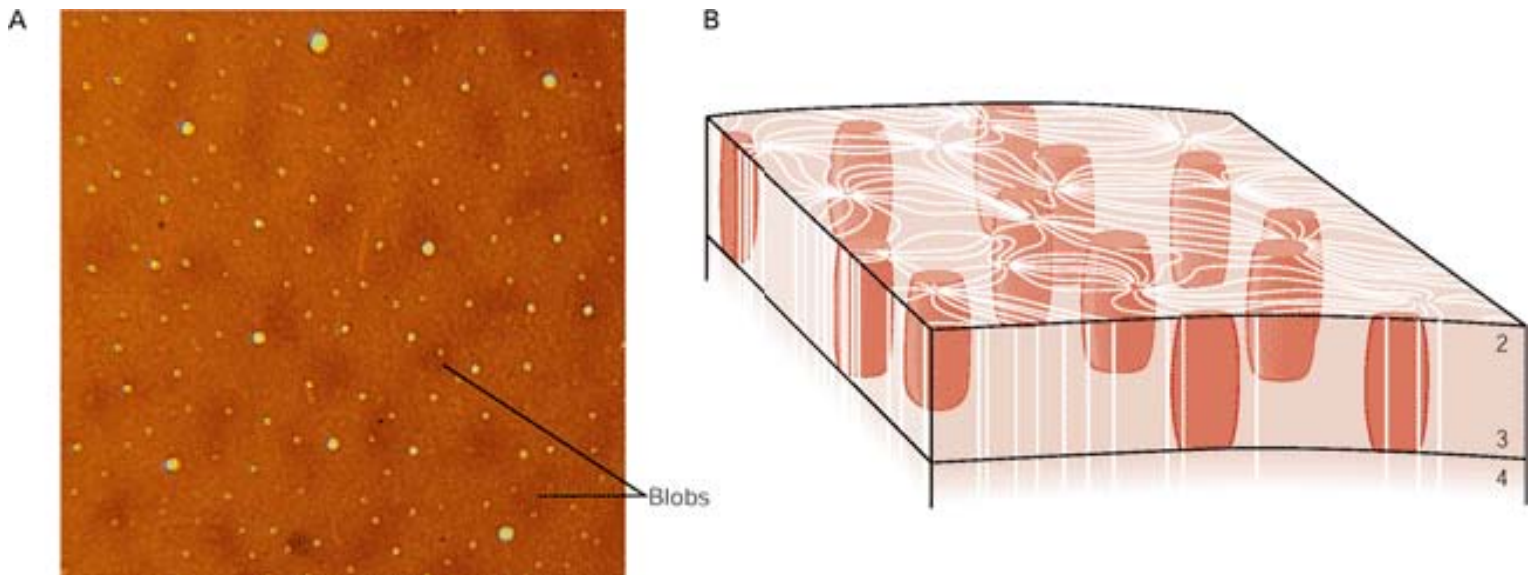


Fig. 57. This illustration shows the organization of blobs in the visual cortex. A. This photomicrograph shows the blobs to be dark patches of a single 40 μm thick layer of upper cortex that has been processed histochemically to reveal the density of cytochrome oxidase, a mitochondrial enzyme involved in energy production. The heightened enzymatic activity in the blobs is thought to represent heightened neural activity. The

cortex was sectioned tangentially. (Courtesy of D. Tó, C. Gilbert, and T. Wiesel.) B. Organization of the blobs in relation to the orientation columns. Only the upper layers of the cortex are shown with the blobs extending through these layers. The blobs interrupt the pattern of the orientation columns.

In addition to columns of cells responsive to bars of light in a particular axis of orientation and blobs, which respond to different color stimuli, there is a third system, which consist of alternating parallel strips, which are arranged perpendicular to the surface of the cortex, approximately 500 μm wide, which receive input from the ipsilateral and contralateral eye. Each parallel strip receives input only from the left or right eye and consequently is important for binocular vision. These alternating parallel strips are arranged in **ocular dominance columns**, within layer 4 of V1. Within each ocular dominance column, either for the left or right eye, the contralateral eye projects to layers 1, 4 and 6; the ipsilateral eye projects to 2, 3 and 5.

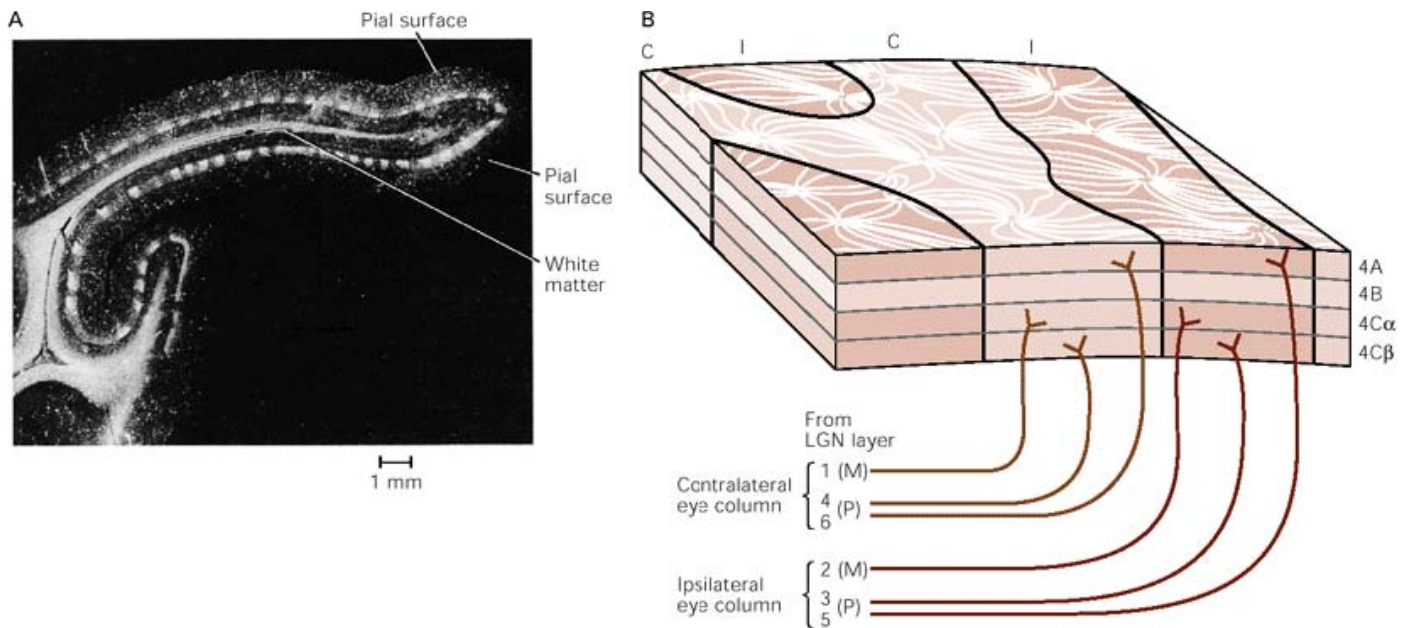


Fig. 58. This figure represents the ocular dominance columns

A. This is an autoradiograph of the primary visual cortex of an adult monkey, which shows the ocular dominance columns as alternating white and dark patches in layer 4 of the cortex, below the pial surface. One eye of the monkey was injected with a cell label, which over the course of 2 weeks was transported to the lateral geniculate nucleus and then across synapses to the geniculocortical relay cells, whose axons

terminate in layer 4 of the visual cortex. Areas of layer 4 that receive input from the injected eye are heavily labeled and appear white; the alternating unlabeled patches receive input from the un-injected eye. In all, some 56 columns can be counted in layer 4C. The underlying white matter appears white because it contains the labeled axons of geniculate cells. (From Hubel and Wiesel 1979)

- B. This scheme of inputs to the alternating ocular dominance columns in layer 4 of the primary visual cortex. Inputs from the contralateral (C) and ipsilateral (I) eyes arise in different layers in the lateral geniculate nucleus (LGN), and project to different subdivisions of layer 4.

A Hypercolumn Represents the Visual Properties of One Region of the Visual Field

The above three columns are further arranged into a functional modular unit, which contains the circuitry for analysis of a given discrete region in the visual field called a **hypercolumn**. Hubel and Wiesel introduced the term hypercolumn to refer to a set of

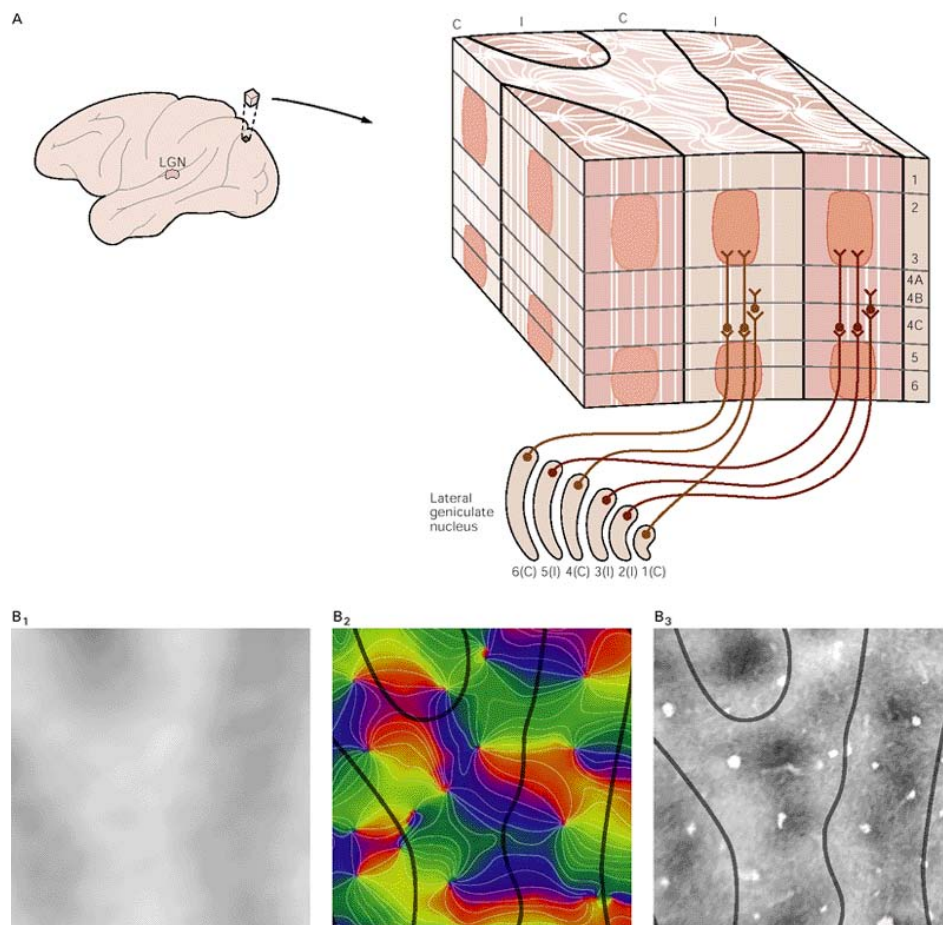


Fig. 59. The above depicts the organization of orientation columns, ocular dominance columns, and blobs in the primary visual cortex.

A. This image constitutes an array of functional columns of cells in the visual cortex, which contains the neural machinery necessary to analyze a discrete region of the visual field and can be thought of as a functional module. Each module contains one complete set of orientation columns, one set of ocular dominance columns (right and left eye), and several blobs (regions of the cortex associated with color processing). The entire visual field can be represented in the visual cortex by a regular array of modules. B. This image depicts ocular dominance columns, orientation columns, and blobs from the same region of the primary visual cortex. (Courtesy of Gary Blasdel.) 1. These images of the ocular dominance columns were obtained using optical imaging and independently stimulating the left and right ocular dominance columns in a particular region. Because neural activity decreases cortical reflectance, the subtraction of one left eye image from one right eye image produces the characteristic pattern of dark and light bands, representing the right and left eyes respectively. 2. In this image the borders of the ocular dominance columns shown in 1 appear as black lines superimposed on the pattern of orientation-specific columns depicted previously. 3. The borders of the ocular dominance columns shown in 1 are superimposed on tissue reacted for cytochrome oxidase, which visualizes the blobs. The blobs are thus seen localized in the centers of the ocular dominance columns.

columns responsive to lines of all orientations from a particular region in space. Each hypercolumn contains a set of nine orientation columns, which comprise a complete cycle of orientation through 180° , an adjoining pair of right and left ocular dominance columns and several blobs. The relationship between the orientation columns, the independent ocular dominance columns, and the blobs within a module is illustrated in the above illustration. A complete sequence of ocular dominance columns and orientation columns is repeated regularly and precisely over the surface of the primary visual cortex, each occupying a region of about 1 mm^2 . This repeating organization is a striking illustration of the modular organization characteristic of the cerebral cortex.

Each module acts as a window on the visual field and each window represents only a tiny part of the visual field, but the whole field is covered by many such windows. Within the processing module all information about that part of the visual world is processed. This includes orientation, binocular interaction, color, and motion.

Each module has a variety of outputs originating in different cortical layers. The organization of the output connections from the primary visual cortex is similar to that of

the somatic sensory cortex in that there are outputs from all layers except 4C, and in each layer the principal output cells are the pyramidal cells, which are depicted in the figure below. The axons of cells above layer 4C project to other cortical areas; those of cells below 4C project to subcortical areas.

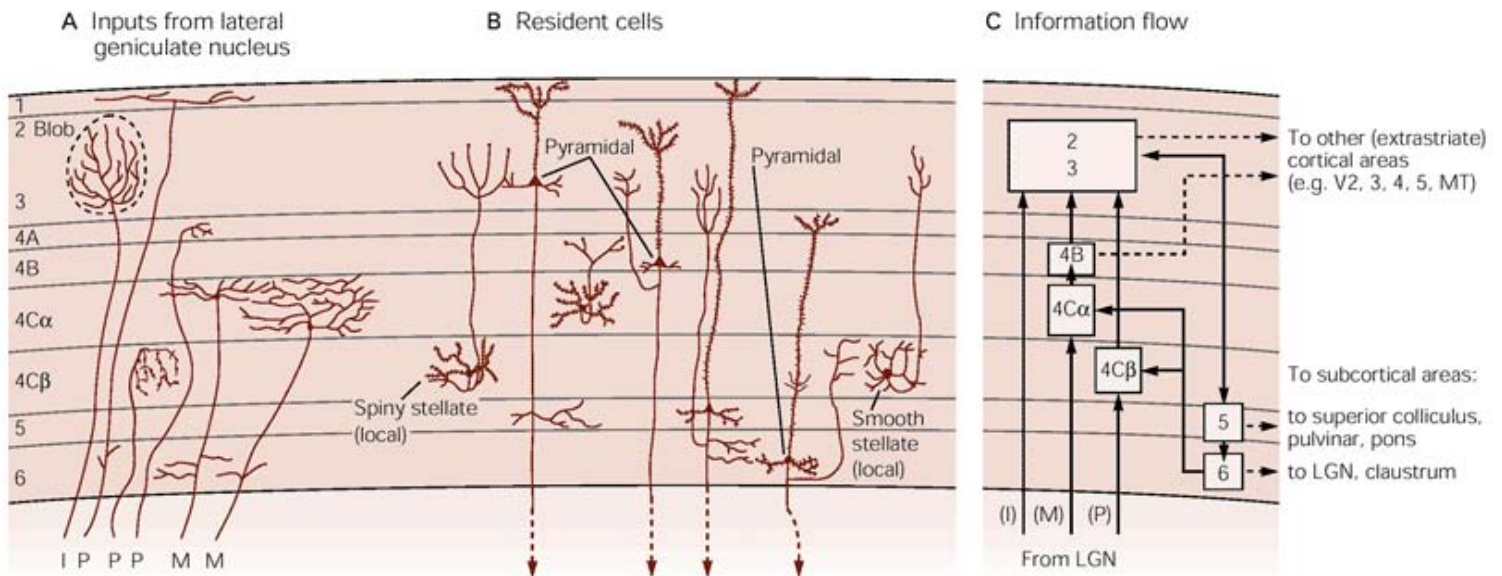


Fig. 60. This illustration shows the distinct anatomical layers of the primary visual cortex, each with characteristic synaptic connections. (Adapted from Lund 1988.)

- This depicts most afferent fibers from the lateral geniculate nucleus terminating in layer 4. The axons of cells in the parvocellular layers (P) terminate primarily in layer 4C, with minor inputs to 4A and 1, while the axons of cells in the magnocellular layers (M) terminate primarily in layer 4C. Collaterals of both types of cells also terminate in layer 6. Cells of the intralaminar regions (I) of the lateral geniculate nucleus terminate in the blob regions of layers 2 and 3.
- Several types of neurons make up the primary visual cortex. Spiny stellate and pyramidal cells, both of which have spiny dendrites, are excitatory. Smooth stellate cells are inhibitory. Pyramidal cells project out of the cortex, whereas both types of stellate cells are local neurons.
- This figure shows the conception of information flow based on anatomical connections. (LGN, lateral geniculate nucleus; MT, middle temporal area.)

Inputs. Axons from the M and P cells in the LGN end on the spiny stellate cells in the sublayers of 4C, and these cells project axons to layer 4B or the upper layers 2 and 3. Axons from cells in the intralaminar zones of the LGN project directly to layers 2 and 3.

Intracortical connections. Axon collaterals of pyramidal cells in layers 2 and 3 project to layer 5 pyramidal cells, whose axon collaterals project both to layer 6 pyramidal cells and back to cells in layers 2 and 3. Axon collaterals of layer 6 pyramidal cells then make a loop to layer 4C onto smooth stellate cells.

Output. Each layer, except for 4C, has outputs for V1 and each is different. The cells in layers 2, 3, and 4B project to extrastriate visual cortical areas. Cells in layer 5 project to the superior colliculus, the pons, and the pulvinar. Cells in layer 6 project back to the LGN and the claustrum.

Once afferents from the LGN enter the primary visual cortex, information flows systematically from one cortical layer to another, starting with the spiny stellate cells, which predominate in layer 4. The spiny stellate cells distribute the input from the LGN to the cortex and the pyramidal cells feed axon collaterals upward and downward to integrate activity within the layers of V1 (the above figure C).

The cells in layers 2 and 3 send their output to other higher visual cortical regions, such as Brodmann's area 18 (V2, V3, and V4). They also make connections via the corpus callosum to anatomically symmetrical cortical areas on the other side of the brain. Cells in layer 4B project to the MT (V5 or MT). Cells in layer 5 project to the superior colliculus, the pons, and the pulvinar. Cells in layer 6 project back to the LGN and to the claustrum.

Since cells in each layer of the visual cortex probably perform a different task, the laminar position of a cell determines its functional properties.

Linkage of the Columnar Units by Horizontal Connections

As of this point we have covered the three major vertically oriented systems which extend across the primary visual cortex: (1) orientation columns, which contain the neurons that respond selectively to light bars with specific axes of orientation; (2) blobs, which are the peg-shaped patches in the upper layers, except for 4, that contain cells that are more concerned with color than orientation; and (3) ocular dominance columns, which receive inputs from one or the other eye. These units are in turn organized into hypercolumns that monitor small areas of the visual field.

These vertically orientated hypercolumns in turn communicate with one another by means of horizontal communications that link cells within each layer with similar

response properties. Axon collaterals of individual pyramidal cells in layers 3 and 5 run long distances, parallel with the layers, and give rise to clusters of axon terminals at regular intervals that approximate the width of the hypercolumn. These horizontal connections integrate information over many millimeters of cortex, thus a cell within each hypercolumn can be influenced by another cell in another hypercolumn that has similar stimuli responsiveness. Thus, a cell within an orientation column of one hypercolumn does not see a stimulus in one axis of orientation in isolation, but sees this stimulus in the context in which this particular stimulus is related to the entire image being visualized. This psychophysical principle is referred to as the “**contextual effect**,” in which we evaluate objects in the context in which we see them and is believed to be mediated by these horizontal connections between the hypercolumns of V1.

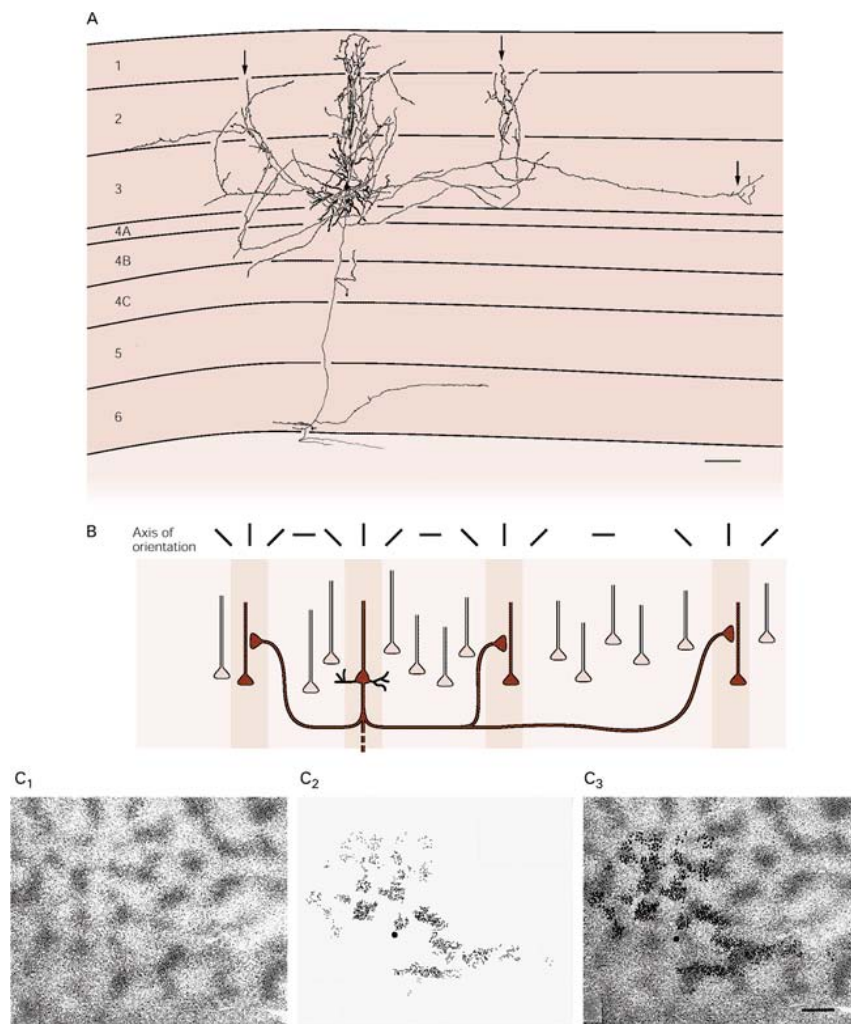


Fig. 61. The above illustration shows column of cells in the visual cortex with similar function are linked through horizontal connections.

- A. This illustration shows pyramidal cells in layers 3 and 4 in a monkey. You will note that several axon collaterals branch off the descending axon near the dendritic tree and in three other clusters (arrows). The clustered collaterals project vertically into several layers at regular intervals, consistent with the sequence of functional columns of cells. (From McGuire et al. 1991.)
- B. This image shows the horizontal connections of a pyramidal cell, such as shown in A, are functionally specific. The axon of the pyramidal cell forms synapses on other pyramidal cells in the immediate vicinity as well as pyramidal cells some distance away. Recordings of cell activity demonstrate that the axon makes connections only with cells that have the same functional specificity. (Adapted from Tóó et al. 1986.)
- C. 1. A section of the cortex labeled with 2-deoxyglucose showing a pattern of stripes representing columns of cells that respond to a stimulus with a particular orientation. 2. Microbeads injected into the same site as in 1 are taken up by the terminals of neurons and transported to the cell bodies. 3. Superimposition of images in 1 and 2. The clusters of bead-labeled cells lie directly over the 2-deoxyglucose-labeled areas, showing that groups of cells in different columns with the same axis of orientation are connected. (From Gilbert and Wiesel 1989.)

Synopsis of Visual Anatomy

As shown above, the visual cortex is organized functionally into two sets of intersecting connections, one vertical, consisting of functional columns spanning the different cortical layers, and the other horizontal, connecting functional columns with the same response properties. It has been demonstrated that these connections integrate information over many millimeters of cortex. As a result, a cell can be influenced by stimuli outside its normal receptive field. Indeed, a cell's axis of orientation is not completely invariant but is dependent on the context on which the feature is embedded. The psycho-physical principle of contextual effect, whereby we evaluate objects in the context in which we see them, is thought to be mediated by the horizontal connections between the functional columns of the visual cortex. Lesions in the Retino-Geniculate-Cortical Pathway are associated with specific gaps in the visual field, which will be discussed under Functional Considerations.

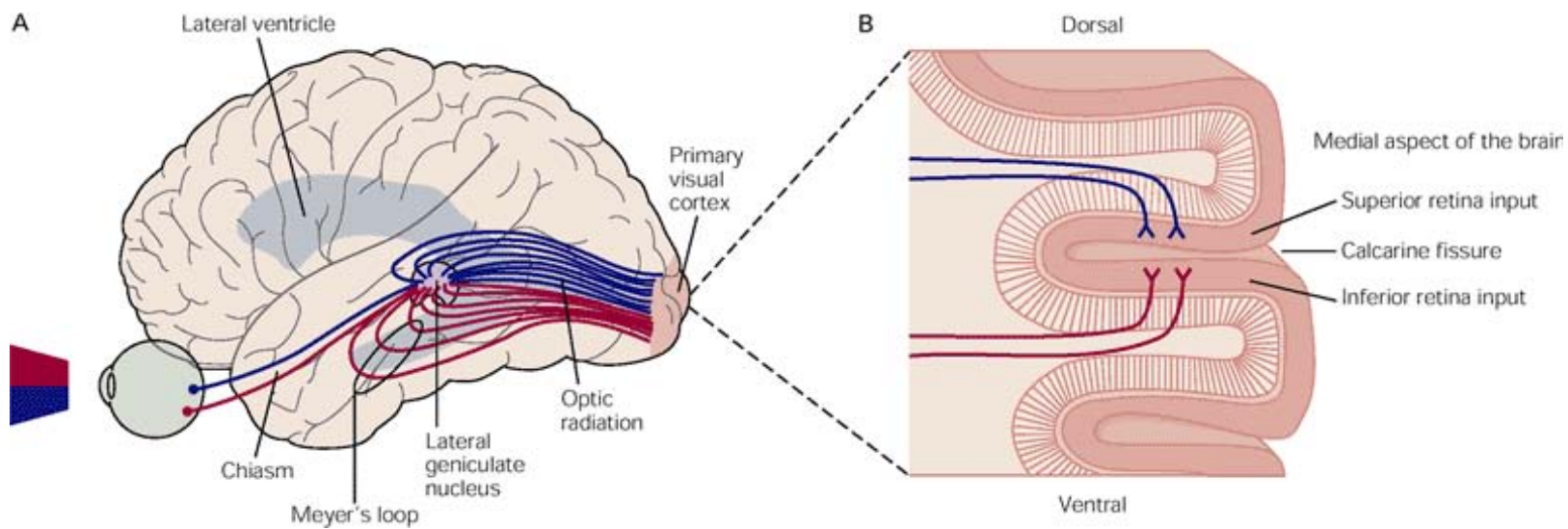


Fig. 62. This figure shows the projection of input from the retina to the visual cortex

- A. This shows fibers from the LGN sweeping around the lateral ventricle in the optic radiation to reach the primary visual cortex. Fibers that relay inputs from the inferior half of the retina loop rostrally around the temporal horn of the lateral ventricle, forming Meyer's loop. (Adapted from Brodal 1981.)
- B. This represents a cross section through the primary visual cortex in the occipital lobe. Fibers that relay input from the inferior half of the retina terminate in the inferior bank of the visual cortex, below the calcarine fissure. Those that relay input from the superior half of the retina terminate in the superior bank.

The axons in the optic tract form synapses on the principle cells of the LGN. In turn, the axons of the principal cells sweep around the lateral ventricle in the optic radiation to the primary visual cortex, radiating on the lateral surface of both the temporal and occipital horns of the lateral ventricle as shown in A of the above figure. Fibers representing the inferior parts of the retina swing rostrally in a broad arc over the temporal horn of the ventricle and loop into the temporal lobe before turning caudally to reach the occipital pole. This group of fibers, called Meyer's loop, relays input from the inferior half of the retina terminating on the inferior bank of the cortex lining the calcarine fissure. The fibers relaying input from the superior half of the retina terminate in the superior bank as shown in B of the above figure. Consequently, unilateral lesions in the temporal lobe affect vision in the superior quadrant of the contralateral visual hemifield. This will be further explored in the following section dealing with Functional Considerations.

FUNCTIONAL CONSIDERATIONS

Retinal, optic nerve, optic chiasm, optic tract, optic radiation and visual cortex injuries have many etiologies, which cause loss of vision, impairment of papillary light reflexes, and abnormalities in papillary size and reactivity. A thorough knowledge of the neuro-anatomy of the visual pathway is needed to understand the localizing value of the visual field test, and also aids the Neuropathologist in his or her examination of the visual pathway to localize the lesion.

The pattern of a visual field defect depends on the composition and configuration of the visual pathway fibers in the affected area. The visual pathway can be divided into three general anatomic regions: prechiasmal (i.e., retina and optic nerve), chiasmal, and post chiasmal regions.

From a clinical perspective the actual visual field defect can be divided into five distinct patterns: central or centrocecal scotoma; arcuate or altitudinal scotoma; temporal wedge scotoma; generalized depression; and hemianopia. Of these five visual field defects only the hemianopia occurs with lesions between the optic chiasm to the occipital lobe. The other four defects are produced by lesions that may be at any location between the retina and the prechiasmal optic nerve.

There are a number of terms which you will see that are utilized to describe visual field defects. **Scotoma** is an area of decreased vision in the seeing field. A visual field defect may be relative or absolute. A relative defect varies in size or density according to the size, color, and intensity of the test stimulus, and an absolute defect is the same for all test targets. The term **homonymous** means the same side of the visual field is affected in each eye, and **hemianopia** refers to one half of the field in which the defect obeys the vertical meridian. If the defect involves one-fourth of the field and obeys the vertical meridian, the term quadrantanopia is used. A homonymous defect may be congruous (i.e., the same in each eye) or incongruous (i.e., shaped differently between the two eyes).

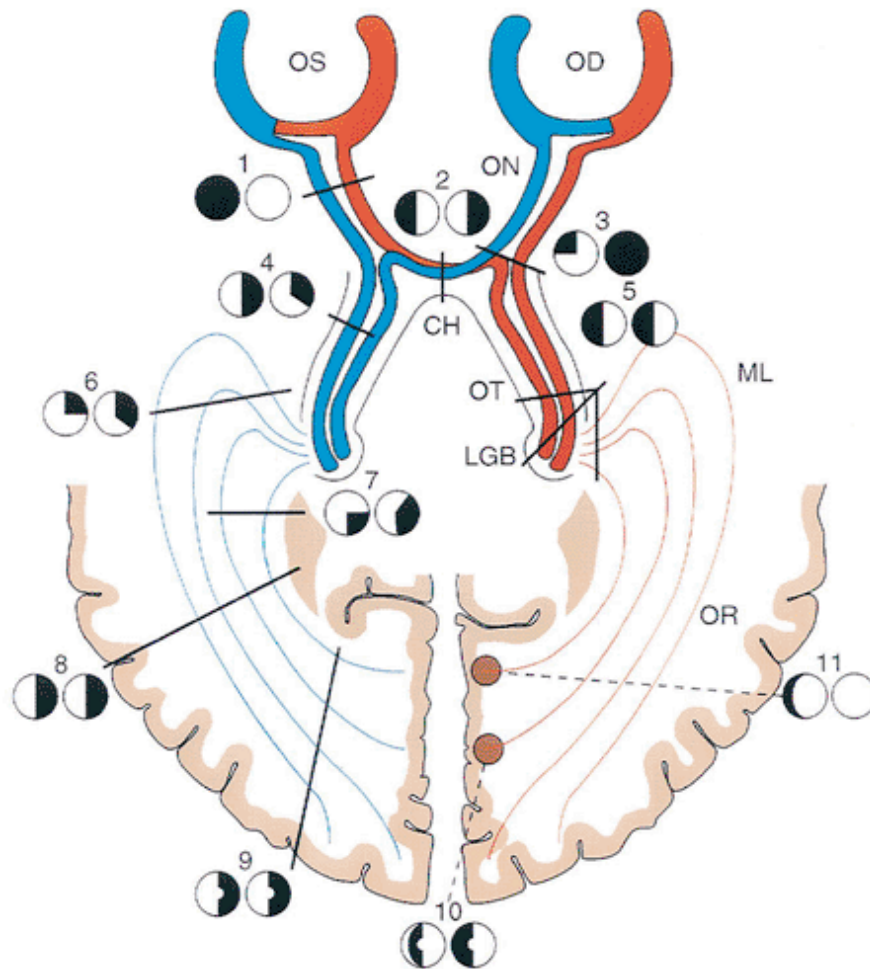


Fig. 63. This is a schematic illustration of the visual pathway and visual field defects produced by lesions in various areas of the pathway. OD, right eye; OS, left eye; ON, optic nerve; CH, chiasm; OT, optic tract; LGB, lateral geniculate body; ML, Meyer's Loop; OR, optic radiations.

1. Compromise of the left optic nerve results in a central scotoma in the left eye, with normal right visual field.
2. A lesion of the optic chiasm may cause a bitemporal hemianopia.
3. A lesion at the junction of the right optic nerve and the chiasm results in a central scotoma in the right eye and a superior visual field defect that respects the vertical meridian in the left eye. This effect results from compromise of the inferior nasal crossing fibers from the left eye, which extend into the prechiasmal portion of the right optic nerve. The resulting visual field defect is known as a junctional scotoma, which is located at the junction of the optic nerve and chiasm.
4. Complete interruption of the optic tract produces a homonymous hemianopic field defect. Subtotal lesions produce highly incongruous homonymous hemianopias.
5. Complete interruption of the optic tract, lateral geniculate body, and optic radiations results in a total contralateral homonymous hemianopia.

6. Fibers originating in the ipsilateral inferior temporal retina and the contralateral inferior nasal retina sweep anteriorly and laterally around the temporal horn (i.e., Meyer's Loop) before transverse posteriorly. As a result, lesions of the temporal lobe characteristically produce superior, often incongruous homonymous quadrantanopias.
7. Parietal lobe lesions may interrupt visual pathway fibers from the superior retinas pursuing a more direct posterior course. This results in an inferior homonymous quadrantanopia.
8. Complete interruption of the optic radiations results in contralateral total homonymous hemianopia.
9. Posterior occipital lobe lesions result in homonymous hemianopic defects, which may spare the macula. Subtotal occipital lesions produce exquisitely congruous visual field defects because the fibers are more highly segregated in the occipital area.
10. Lesions affecting the posterior portion of the occipital lobe may spare the more anteriorly placed unpaired crossing peripheral nasal retinal fibers, resulting in a preserved temporal crescent in an otherwise congruous homonymous hemianopia.
11. Focal lesions involving the anterior-most portion of the occipital lobe may affect the receptive area for the unpaired crossing fibers from the contralateral nasal retina, resulting in a unilateral peripheral temporal visual field defect.

(Modified from Harrington DO, Drake MV. The visual fields: Text and Atlas of Clinical Perimetry. 6th ed. St. Louis: CV Mosby; 1990, with permission.)

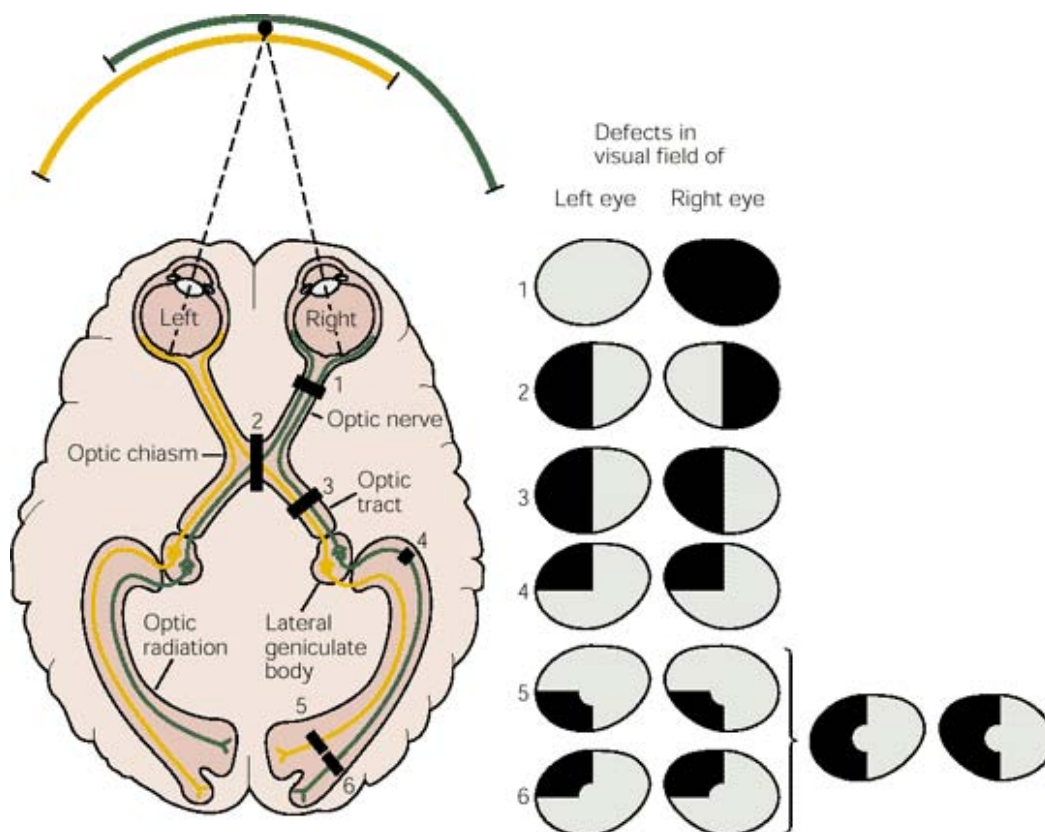


Fig. 64. The above is another schematic illustration, which shows an additional visual defect, numbers 5 and 6, which constitute partial lesions of the visual cortex leading to partial field defects on the opposite side. A lesion in the upper bank of the calcarine sulcus (5) causes a partial deficit in the inferior quadrant of the visual field on the opposite side. A lesion in the lower bank of the calcarine sulcus (6) causes a partial deficit in the superior quadrant of the visual field on the opposite side. A more extensive lesion of the visual cortex, including parts of both banks of the calcarine cortex, would cause a more extensive loss of vision in the contralateral hemifield. The central area of the visual field is unaffected by cortical lesions (5 and 6), probably because the representation of the foveal region of the retina is so extensive that a single lesion is unlikely to destroy the entire representation. The representation of the periphery of the visual field is smaller and hence more easily destroyed by a single lesion.

The above schematic illustrations demonstrate a key point in visual processing: At the initial stages of visual processing each half of the brain is concerned with the contralateral hemifield of vision. This pattern of organization begins with the segregation of axons in the optic chiasm, where fibers from the two eyes dealing with the same part of the visual field are brought together. In many respects, this is similar to the somatic sensory system, in which each hemisphere mediates sensation on the contralateral side of the body.

To summarize the above illustration, after sectioning one optic nerve the visual field is seen monocularly by the eye on the intact side (1).

The temporal crescent is normally seen only by the nasal hemiretina on the same side. A person whose optic nerve is cut would therefore be blind in the temporal crescent on the lesioned side. Removal of binocular input in this way also affects the perception of spatial depth (stereopsis).

Destruction of the fibers crossing in the optic chiasm removes input from the temporal portions of both halves of the visual field. The deficit produced by this lesion is called bitemporal hemianopsia and occurs because fibers arising from the nasal half of each retina have been destroyed (2). This kind of damage is most commonly caused by a tumor of the pituitary gland that compresses the chiasm.

Destruction of one optic tract produces homonymous hemianopsia, a loss of vision in the entire contralateral visual hemifield.(3). For example, destruction of the right tract causes

left homonymous hemianopsia, i.e., loss of vision in the left nasal and right temporal hemiretinas (4). Finally, a lesion of the optic radiation or of the visual cortex, where the fibers are more spread out, produces an incomplete or quadrantic field defect, a loss of vision in part of the contralateral visual hemifield (5 & 6).

To specify a locus within the visual field, a polar coordinate system is used, all expressing from the ophthalmologist doing the examination of the eyes. The origin corresponds to the point on which the ophthalmologist is fixating. The polar angle is considered to be zero degrees when a locus is horizontally to the right of the fixation point and to increase to a maximum of 360 degrees going anticlockwise. Distance from the origin is given in degrees of visual angle; it's a measure of eccentricity. Each polar axis is a meridian of the visual field. For example, the **horizontal meridian** runs from the ophthalmologist's left, through the fixation point, and to the ophthalmologist's right. The **vertical meridian** runs from above the ophthalmologist's line of sight, through the fixation point, and to below the ophthalmologist's line of sight. The meridian of the visual field influences the folding of the cerebral cortex. In both the V1 and 2 areas of humans, the vertical meridian of their visual field tends to be represented on the cerebral cortex's convex gyri folds, whereas the horizontal meridian tends to be represented in their concave sulci folds.

The term **retinal raphe** refers to a horizontal line of demarcation, on the temporal side of the macula, separating the arcuate nerve fibers from the upper and lower retina.

Impairment of vision of ocular origin can be due to refractive error, opacity of the ocular media, or a retinal abnormality such as retinal detachment, inflammation, hemorrhage and vascular occlusion. Disorders of the retina cause disturbance in vision but neither pain nor inflammation of the eye.

PRECHIASMAL VISUAL FIELD DEFECTS

A transient or sudden loss of vision of **retinal etiology** is typically due to a **transient ischemic attack of the retina (amaurosis fugax)**. Patients describe a rapid fading of vision, which may only affect a portion of the visual field. This is usually due to an embolus within a retinal arteriole. If the embolus dislodges and blood flow is restored,

vision will return to normal with no permanent damage. However, with prolonged interruption of blood flow the inner retina becomes infarcted with permanent loss of vision, the degree of which is determined by the retinal field affected. As an example, if the nasal hemiretina is damaged vision is lost in the entire temporal crescent in the same eye (ipsilateral). Damage to the inferior half of the retina of one eye causes a monocular defect in the upper half of the visual field of that eye. Damage to large regions of the peripheral retina gives rise to a loss of vision, which is often identified through the person accidentally bumping into an unnoticed object. Amaurosis fugax can also occur from low central retinal artery perfusion pressure in a patient with a critical stenosis of the ipsilateral carotid artery accompanied by poor collateral flow in the circle of Willis. In this situation, amaurosis fugax develops when there is a sudden decrease in blood pressure or even slight worsening of the carotid stenosis. Sometimes this is accompanied by contralateral motor or sensory loss, indicating concomitant hemispheric cerebral ischemia. Retinal arterial occlusion can also be seen in intravenous drug abuse. A sudden increase in blood pressure can give rise to vasospasm of retinal arterioles and retinal ischemia; it can also produce visual loss through ischemic swelling of the optic disc.

Developing occlusion of a branch of or the central vein can produce visual field defects that are identical to those of amaurosis fugax. In some patients, venous flow returns spontaneously, while others evolve frank obstruction with extensive retinal bleeding and permanent loss of vision. Venous occlusion of the retina is often idiopathic, however, hypertension, diabetes, and glaucoma are important risk factors.

Another sudden, painless, monocular loss of vision is **decrease blood flow through the posterior ciliary arteries supplying the optic disc**, giving rise to **anterior ischemic optic neuropathy (AION)**. There are two forms of AION: nonarteritic and arteritic. The nonarteritic is most common; it has no underlying causation although it is associated with diabetes and hypertension. The arteritic form occurs in conjunction with giant cell (temporal) arteritis. In this form high doses of glucocorticoids can prevent blindness.

A major loss of blood, such as that caused by exsanguinating trauma, gastrointestinal hemorrhage or surgery can cause a sudden loss of vision. This condition is referred to as **posterior ischemic optic neuropathy**. Vision can be restored in some patients by rapid blood transfusion.

Optic neuritis is a common inflammatory disease of the optic nerve, which can give rise to a sudden decrease in visual acuity. It is typically caused by inflammation, degenerative, demyelinating, or toxic disorders. These patients present with decreased visual acuity and predominant central field of vision loss. It typically presents spontaneously and generally in a limited fashion with virtually all patients experiencing a gradual recovery of vision after a single episode even without treatment. This clinical feature is so consistent that should vision not return after the first attack of optic neuritis than the original diagnosis is open to question.

Toxic optic neuropathy can result in acute visual loss manifested by bilateral optic disc swelling and central or cecentral scotomas. Such cases have been reported to result from exposure to ethambutol, methyl alcohol (moonshine), ethylene glycol (antifreeze), or carbon monoxide.

Retinal detachment produces symptoms of floaters, flashing lights, and a scotoma in the peripheral visual field corresponding to the detachment. If the detachment includes the fovea there is a loss in visual acuity. In most eyes, retinal detachment starts with a hole, flap, or tear in the peripheral retina. Once a defect has developed in the retina, liquefied vitreous enters the subretinal space, separating the retina from the pigment epithelium. The combination of vitreous traction upon the retinal surface and passage of fluid behind the retina leads to detachment.

Vertebrobasilar insufficiency can give rise to transient ischemic attacks manifested by acute homonymous visual symptoms. Interruption of blood supply to the visual cortex causes a sudden fogging or graying of vision, occasionally with flashing lights. Cortical ischemic attacks are briefer in duration than the visual symptoms associated with migraine, occur in older patients, and are not followed by headache. They may be

associated with signs of brainstem ischemia, such as diplopia, vertigo, numbness, weakness, or dysarthria.

A prolonged interruption of blood supply from the posterior cerebral artery to the visual cortex can give rise to a **stroke**. Occipital lobe stroke is usually due to thrombotic occlusion of the vertebrobasilar system, embolus, or dissection.

Pupillary Reflexes

Pupillary reflexes are clinically important because they indicate the functioning state of the afferent and efferent pathways mediating them. As an example, if light directed to the left eye of a patient elicits a consensual (similar response) in the right eye, but not a direct response in the left eye, then the afferent limb of the reflex, the optic nerve, is intact but the efferent limb to the left eye is damaged, possibly due to a lesion in the oculomotor nerve. In contrast, if the afferent optic nerve is transected, illumination of the affected eye will cause no change in either pupil, but illumination of the normal eye will elicit both direct and consensual responses in both eyes. The pupillary light reflex will not be affected by lesions of the visual pathway above the brachium of the superior colliculus. The absence of pupillary reflexes in an unconscious patient is a symptom of damage to the midbrain, which is the region the oculomotor nerve originates.

Optic Nerve

Lesions of the optic nerve will cause complete blindness in that eye and a loss of the pupillary light reflex. As previously indicated, the pupil will, however, contract consensually to light entering the other eye, due to the fact the pretectal reflex center is related bilaterally to visceral nuclei of the oculomotor complex.

OPTIC CHIASM DEFECTS

Lesions of the optic chiasm may cause several kinds of heteronymous defects. Most commonly the crossing fibers from the nasal portions of the retina are involved, with consequent loss of the two temporal fields of vision; this is called bitemporal hemianopsia. Rarely, both lateral angles of the chiasm may be compressed; in such cases the nondecussating fibers from the temporal retina are affected, and the result is a loss of the nasal visual fields (binasal hemianopsia). Because the chiasm carries crossing fibers

from both eyes, this is the only lesion in the visual system that causes a non-homonymous deficit in vision, i.e., a deficit in two different parts of the visual field resulting from a single lesion.

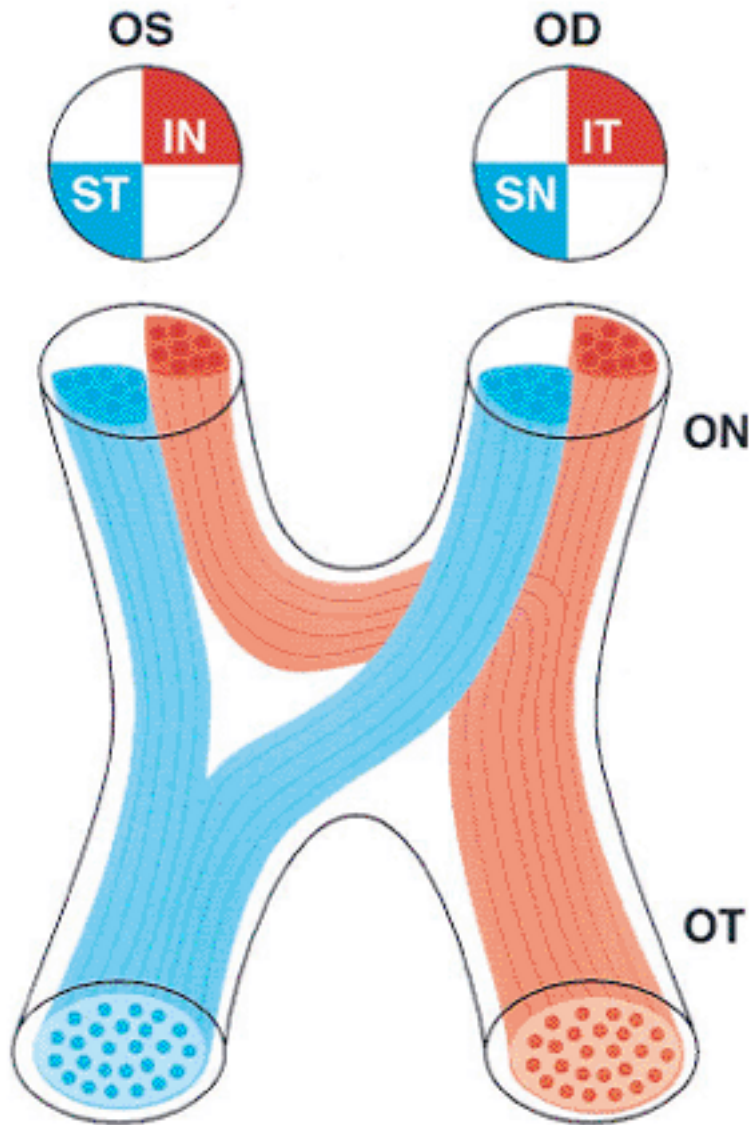


Fig. 65. The above is a schematic illustration of the crossing fibers in the optic chiasm. The inferior nasal fibers from the left eye extend into the prechiasmatal right optic nerve, forming Wilbrand's knee. ON, optic nerve; OT, optic tract; IN, inferior nasal; ST, superior temporal; IT, inferior temporal; SN, superior nasal. (Modified from Glaser JS. Anatomy of the visual sensory system. In: Tasman W, Jaeger EA, eds. Clinical Ophthalmology, vol 2. 1994:4.)

Before we continue I think it is important we again review the terms commonly used to describe visual defects. Visual defects are said to be homonymous, when restricted to a single visual field, right or left, and heteronymous when parts of both fields are involved. Lesions on one side anywhere behind the chiasm cause homonymous defects, i.e., optic tract, lateral geniculate nucleus, optic radiations and visual cortex. Complete destruction of any of these structures results in a loss of the whole opposite field of vision, which is called homonymous hemianopsia; partial injury may produce quadrantic homonymous defects. Quadrantic defects represent a loss of vision in a quarter section of the visual field of one or both eyes; if bilateral, it may be homonymous or heteronymous, binasal or bitemporal, or crossed, e.g. involving the upper quadrant in one eye and the lower quadrant in the other.

POSTCHIASMAL VISUAL FIELD DEFECTS

Optic Tract

A lesion in the optic tract causes a complete loss of vision in the opposite half of the visual field (contralateral hemianopsia), thus if the lesion involves the left optic tract, there is a complete loss of vision on the right side. As previously indicated, fibers from the optic tract terminate principally in the lateral geniculate nucleus, superior colliculus, and the pretectum.

Lateral Geniculate Nucleus (LGN)

Each layer of the LGN receives input from one eye only: fibers from the contralateral nasal hemiretina contact layers 1, 4 and 6; fibers from the ipsilateral temporal hemiretina contact layers 2, 3 and 5. Thus, although one LGN carries complete information about the contralateral visual field, the inputs from that eye remain segregated. The inputs from the nasal hemiretina of the contralateral eye represents the complete contralateral visual hemifield, whereas the inputs from the temporal hemiretina of the ipsilateral eye represent only 90% of the hemifield because they do not include the temporal crescent.

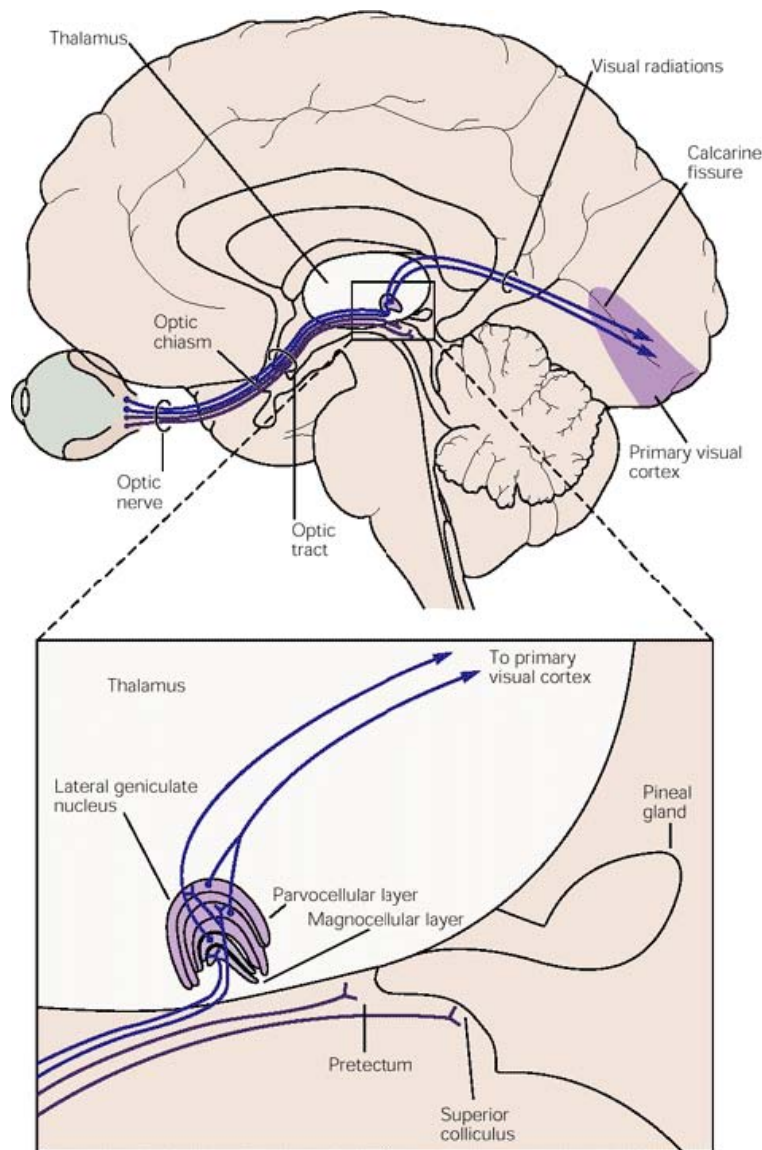


Fig. 66. This is a simplified diagram of the projections from the retina to the visual areas of the thalamus (LGN) and midbrain (pretectum and superior colliculus). The retinal projections to the pretectal area is important for pupillary reflexes, and the projections to the superior colliculus contributes to visually guided eye movements. The projections to the LGN, and from there to the visual cortex, processes visual information for perception.

Superior Colliculus

Each superior colliculus receives visual input from the contralateral visual field. In addition, it receives ipsilateral projections from the visual cortex supplying information concerning only the contralateral visual field. These two systems are precisely and topographically organized at all levels. Unilateral lesions of the SC produce: relative

neglect of stimuli in the contralateral visual field; deficits in perception involving spatial discriminations and tracking of moving objects; heightened responses to stimuli in the ipsilateral visual field, and no impairments of eye movements. These disturbances indicate the SC contributes to the coordination of head and eye movements used to localize and follow visual stimuli. However, in those who sustain damage to the visual cortex, the SC can only respond to stimuli in the contralateral eye; consequently, the SC cannot perform its normal function as a detector of specific movements within the visual field when deprived of input from the visual cortex. The SC is also involved in contralateral conjugate deviations of the eyes (turning of the eyes in parallel and at the same time). This is despite the fact the SC has no projections to nuclei of the extraocular muscles. This response may be due to the projections of the SC to the interstitial nucleus of Cajal, which in turn projects to the contralateral oculomotor nuclei or due to the SC projections to the pontine paramedian reticular formation, which projects to the ipsilateral abducens nucleus, which in turn projects to the oculomotor nucleus. Conjugate deviation can also be an indicator of a pathologic condition in which both eyes are turned to the same side as the result of unilateral infarction of the paramedian reticular formation and abducens nucleus. The SC are involved in coding the location of an object relative to the fovea and in eliciting saccadic eye movements that produce foveal acquisition of the object.

Pretectal Region

The nuclei of the pretectal region include: the nucleus of the optic tract; the subliniform nucleus; the nucleus of the pretectal area; the pretectal olivary nuclei and the principal pretectal nucleus. These nuclei collectively receive fibers from the optic tract, the lateral geniculate nucleus, and certain areas of the cortex and probably the posterior thalamic nuclei. The pretectal region is considered to be the principal midbrain center involved in pupillary light reflex. Fibers from the pretectal olivary nucleus, which receives both, crossed and uncrossed retinofugal fibers, cross in the posterior commissure and project to the visceral nuclei of the oculomotor complex. The pretectal olivary nucleus is the main source of afferents to the visceral nuclei of the oculomotor complex. Fibers from the

nucleus of the posterior commissure, projecting bilaterally to the other visceral nuclei, partially decussate ventral to the cerebral aqueduct. Because of the complex crossed and uncrossed projections to the visceral nuclei of CN III, only relative large lesions involving multiple structures in the pretectum impair the pupillary light reflex.

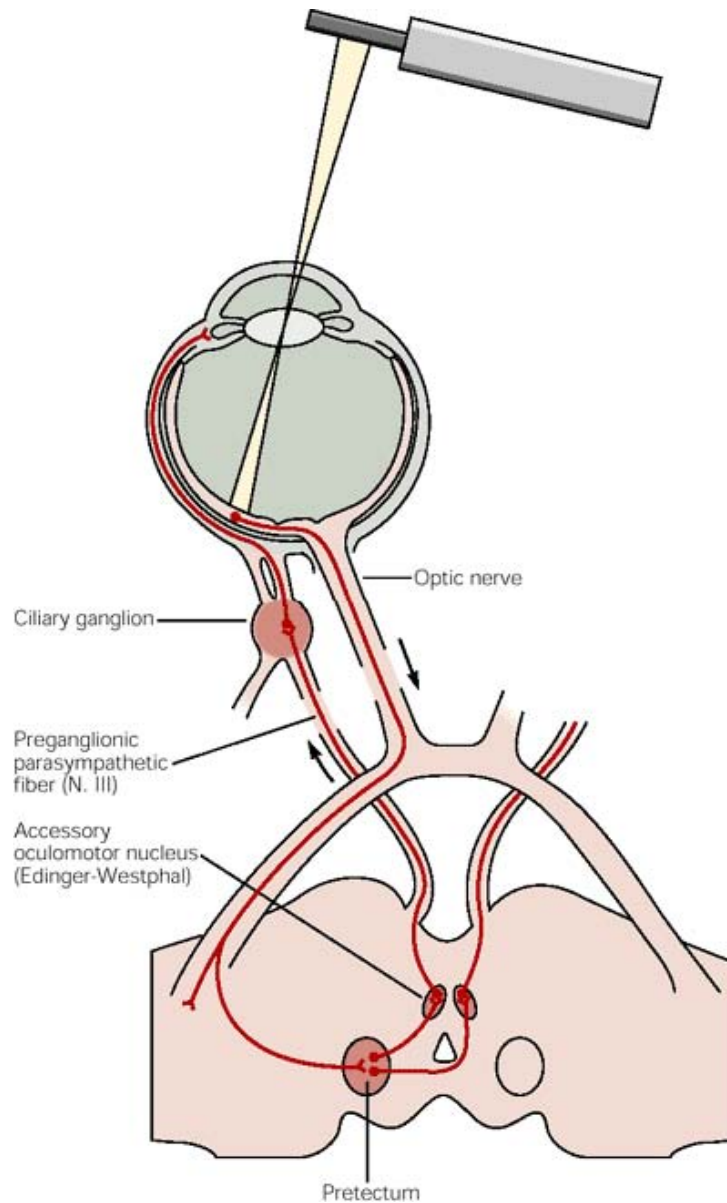


Fig. 67. The above illustration depicts the reflex pathway mediating pupillary constriction. Light signals are relayed through the midbrain pretectum, to preganglionic parasympathetic neurons in the Edinger-Westphal nucleus, and out through the parasympathetic outflow of the oculomotor nerve (CNIII) to the ciliary ganglion. Postganglionic neurons then innervate the smooth muscle of the pupillary sphincter.

Optic Radiations

After leaving the LGN the fibers representing both retinas mix in the optic radiations. Fibers representing the inferior parts of the retina swing rostrally in a broad arc over the temporal horn of the ventricle and loop into the temporal lobe before turning caudally to reach the occipital pole. This group of fibers is called Meyer's Loop, which relays input from the inferior half of the retina to the inferior bank of the cortex lining the calcarine fissure. The fibers representing input from the superior half of the retina terminate in the superior bank. Consequently, unilateral lesions in the temporal lobe affect vision in the superior quadrant of the contralateral visual hemifield because they disrupt Meyer's loop. This defect causes a loss of vision in the upper quadrant of the opposite half of the visual field in both eyes (upper contralateral quadrantic anopsia). A lesion in the inferior bank of the calcarine cortex causes a defect in the superior half of the contralateral visual field.

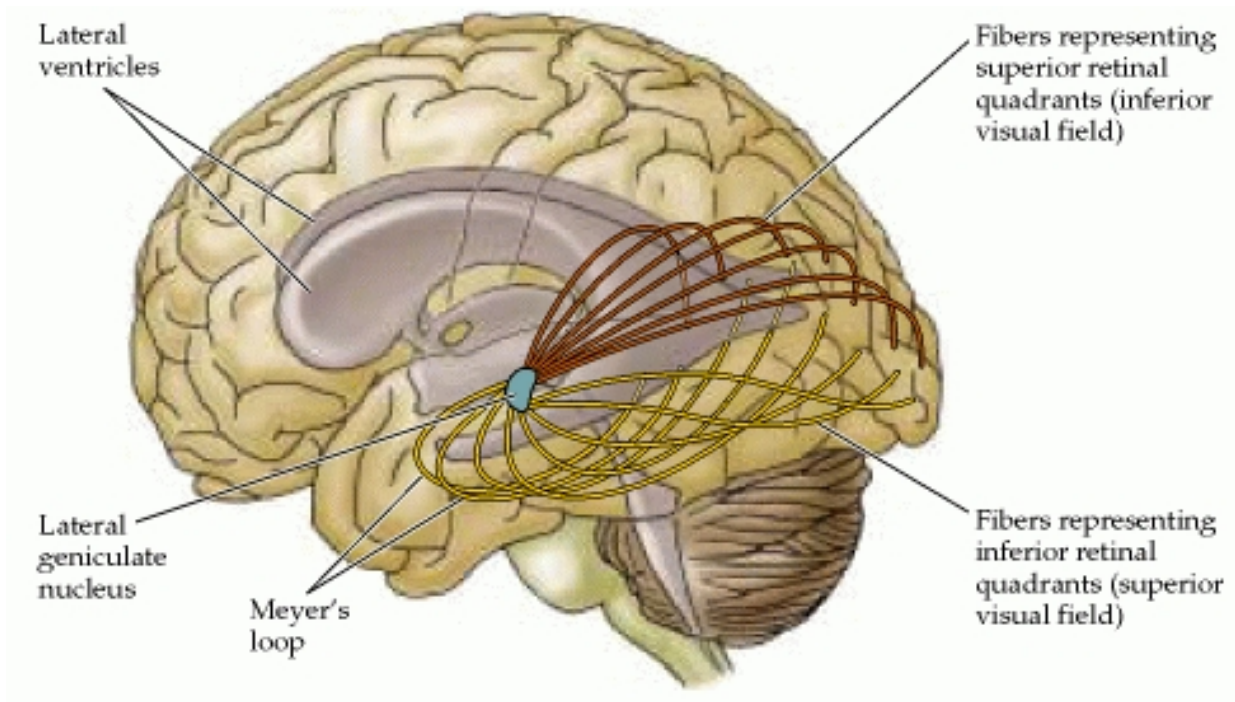


Fig. 68. This figure shows the course of the optic radiations to the striate cortex. Axons carrying information about the superior portion of the visual field sweep around the lateral horn of the ventricle in the temporal lobe (Meyer's loop) before reaching the occipital lobe. Those carrying information about the inferior portion of the visual field travel in the parietal lobe.

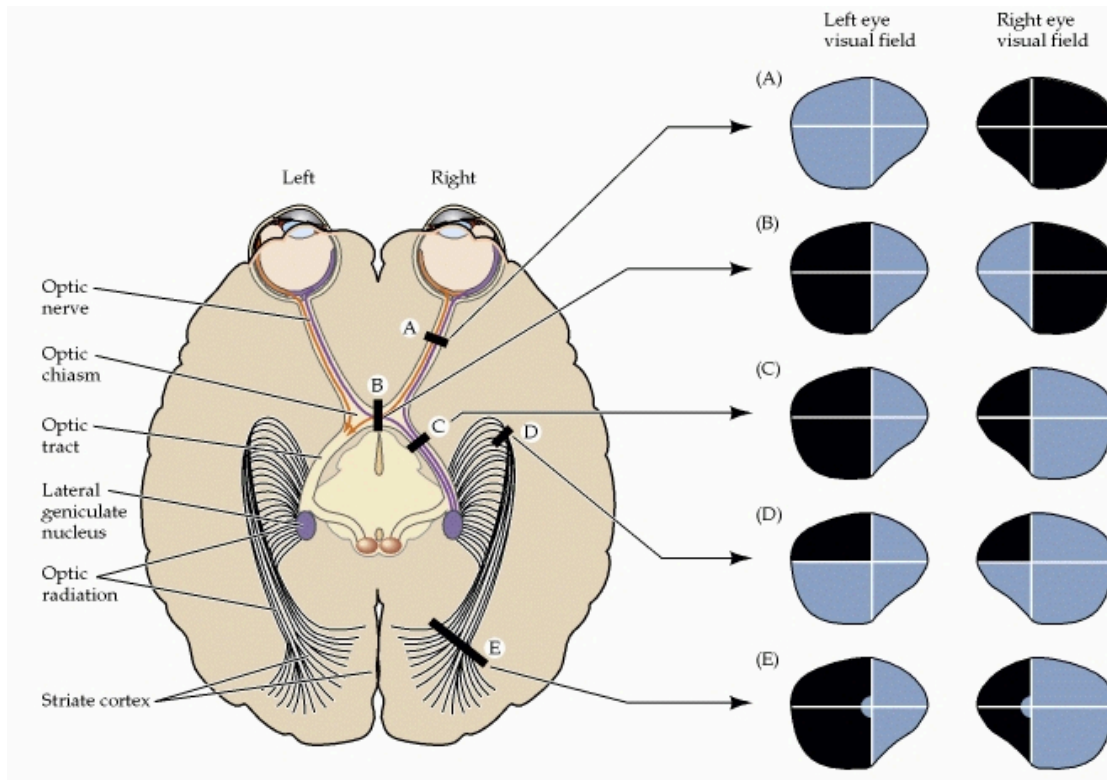


Fig. 69. This figure depicts visual field deficits resulting from damage at different points along the primary visual pathway. The diagram of the left illustrates the basic organization of the primary visual pathway and indicates the location of various lesions. The right panels illustrate the visual field deficits associated with each lesion. (A) Loss of vision in the right eye. (B) Bitemporal (heteronomous) hemianopsia. (C) Left homonymous hemianopsia. (D) Left superior quadrantanopsia. (E) Left homonymous hemianopsia with macular sparing.

Visual Cortex

Complete unilateral destruction of the visual cortex produces a contralateral homonymous hemianopia in which there is blindness in the ipsilateral nasal field and the contralateral temporal field. Thus, a lesion in the right visual cortex produces a left homonymous hemianopsia. Lesions involving portions of the visual cortex, such as the inferior calcarine cortex produce a homonymous quadrantic anopsia, in which a partial deficit in vision occurs in the superior half of the visual field contralaterally. A partial deficit in the superior quadrant of the calcarine sulcus causes a partial deficit in the inferior quadrant of the visual field on the opposite side (contralateral).

The central area of the visual field is unaffected by partial lesions, which is probably because the representation of the foveal region of the retina is so large that a single lesion is unlikely to destroy the entire representation. The representation of the peripheral visual field is smaller and hence more easily destroyed by a single lesion. Homonymous hemianopia can also result from lesions involving all fibers of either optic tract or the optic radiations, but lesions in these locations tend to be incomplete and the visual field defects in the two eyes are rarely identical. Bilateral destruction of the visual cortex leads to total blindness.

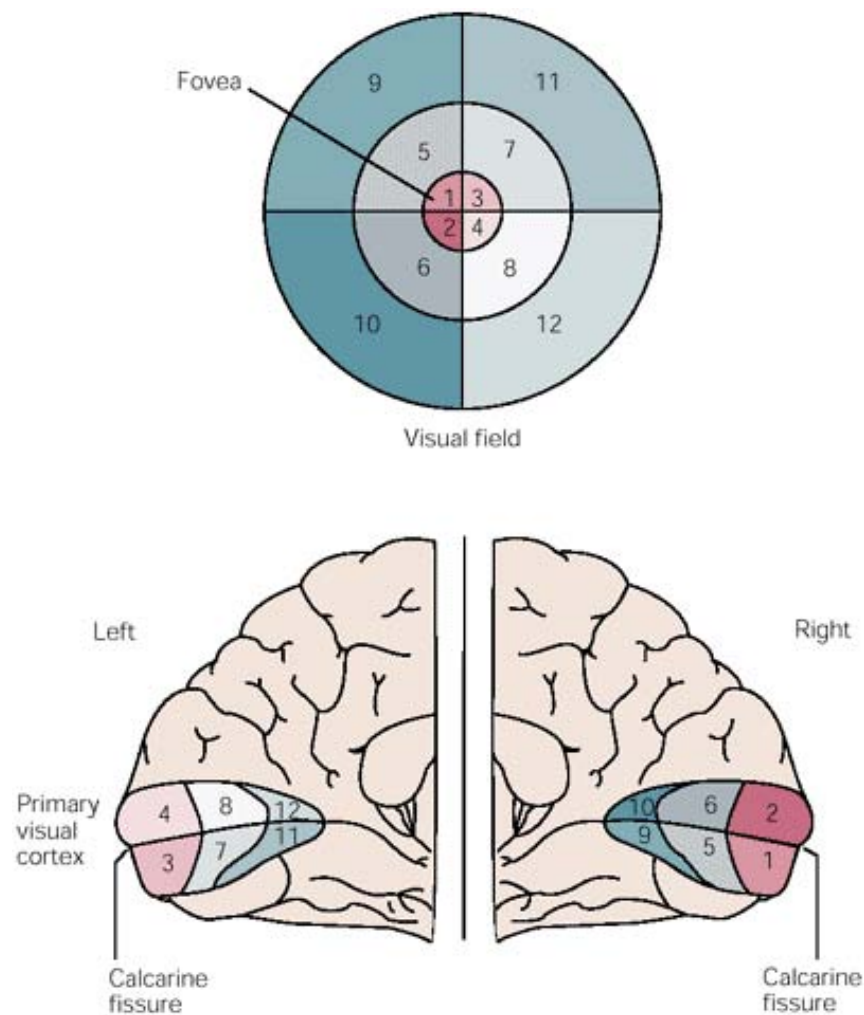


Fig. 70. In this illustration each half of the visual field is represented in the contralateral primary visual cortex. The primary visual field is located at the posterior pole of the cerebral hemisphere and lies almost exclusively on the medial surface, although, in some it is shifted so that part of it extends onto the lateral surface. Areas in the primary

visual cortex are devoted to specific parts of the visual field, as indicated by the corresponding numbers. The upper fields are mapped below the calcarine fissure, and the lower fields above it. What is important to remember is that about half of the neural mass is devoted to representation of the fovea and the region just around it. This area has the greatest visual acuity.

Overview

Information of an object that we visualize passes from the retina to the LGN. In both the retina and the LGN there are cells, which have identical small circular receptive fields. The primary visual cortex takes the information projected from each circular receptive field and elaborates that information in at least three ways. (1) Each part of the visual field is fragmented into linear segments of different orientation in orientation columns. This process is believed to be necessary for the discrimination of form. (2) The processing of color information occurs within structures called blobs. (3) The information from both eyes is assimilated in ocular dominance columns, which gives rise to the perception of depth.

The ability for the visual system to parallel process information is accomplished through very specific central connections. The ganglion cells in the retina project to the LGN in a very precise fashion, such that a complete retinotopic presentation of the visual field for each eye is created. The M and P ganglion cells of the retina project to different layers of the LGN; the M cells project to the two most ventral layers (1 & 2), which are referred to as the magnocellular layers. The P ganglion cells project to the four dorsal layers (3, 4, 5 & 6), which are known as the parvocellular layers. Cells in each of these layers in turn project primarily to different sublayers in 4C of the striate cortex, although, the P cells do have a small projection to 4A. The M cells project to 4C α and the P cells primarily to 4C β . Thus, there are two separate pathways, the M and P pathways, which extend from the retina to the primary visual cortex. The functional contribution to vision differs in each of these pathways. The M pathway is more sensitive to stimuli with lower spatial and higher temporal frequencies. The P pathway is especially sensitive to stimuli with higher spatial and lower temporal frequencies.

There is a third group of cells in the intralaminar region of the LGN referred to as koniocellular cells, the axons of which terminate in layers 2 and 3 of the primary visual cortex, where they innervate patches of cells called blobs, which respond to different color stimuli. It is believed these cells form a third pathway to the visual cortex. They are part of the system that tells the brain what something is. As one would suspect since they innervate cells composing blobs, their principal role is to determine color. There is also a thought they may play a role in integrating somatosensory system proprioceptive information with visual perception.

After the LGN axons terminate on their specific neurons, the neurons within the primary visual cortex, communicate with one another. Axon collaterals of pyramidal cells in layer 2 and 3 project to layer 5 pyramidal cells, whose collaterals project both to layer 6 pyramidal cells and back to cells in layers 2 and 3. Axon collaterals of layer 6 pyramidal cells then make a loop back to layer 4C onto smooth stellate cells.

Following termination of the LGN axons in specific layers of the primary visual cortex, each respective layer of the primary visual cortex in turn projects to other areas of the brain. The cells in layers 2, 3, and 4 β project to the extrastriate visual cortical areas. Cells in layer 5 project to the superior colliculus, the pons, and the pulvinar. Cells in layer 6 project back to the LGN.

Once afferents from the LGN enter the primary visual cortex, information flows systematically from one cortical layer to another, starting with the spiny stellate cells, which predominate in layer 4. The spiny stellate cells distribute the input from the LGN to the cortex and the pyramidal cells feed axon collaterals upward and downward to integrate activity within the layers of V1.

The integration of the flow of information within the layers of V1 occurs through an arrangement of the cells in V1 into vertically orientated functional modules: orientation-specific columns, blobs and ocular dominance columns. Neurons with similar response properties in different vertically oriented modules are in turn linked by horizontal connections. Thus, information within V1 flows in two directions: vertically between layers and horizontally throughout each layer. This pattern of interconnection links

several columnar modules together into hypercolumns, which appear to function as computation modules in that they receive varied inputs, segregate them, and then send the results of their computations to different regions of the brain.